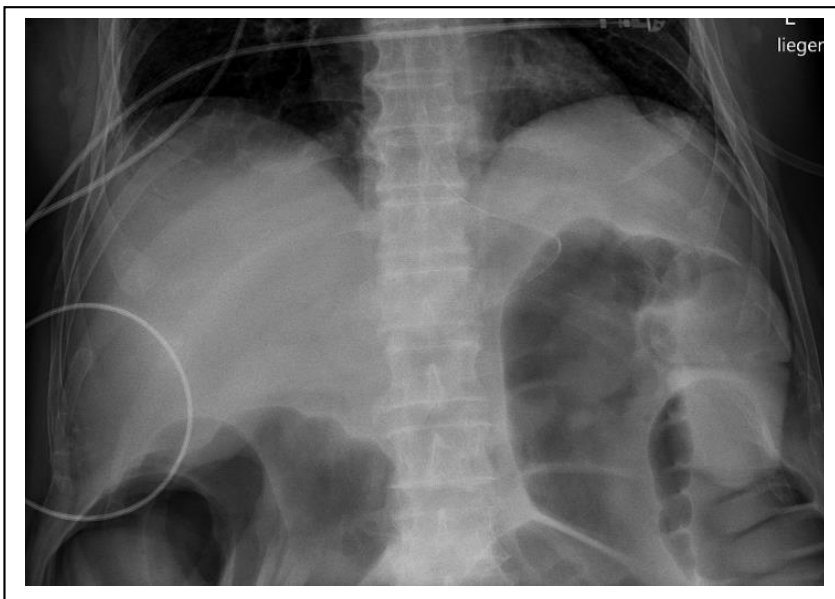
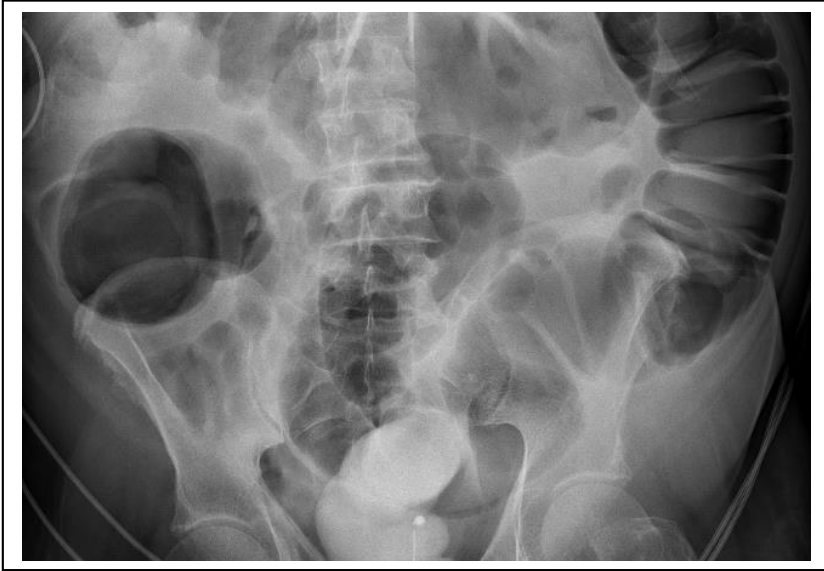
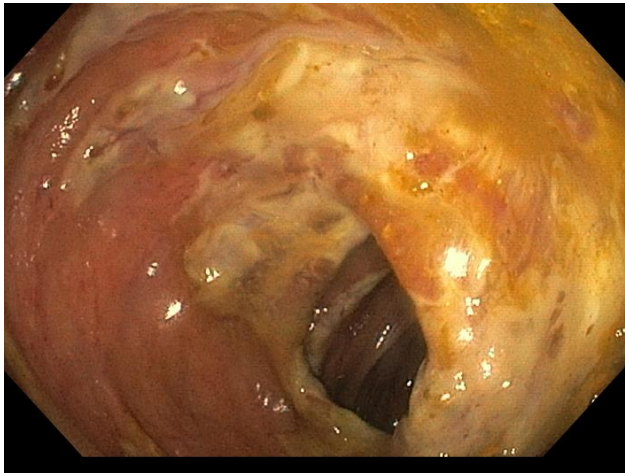

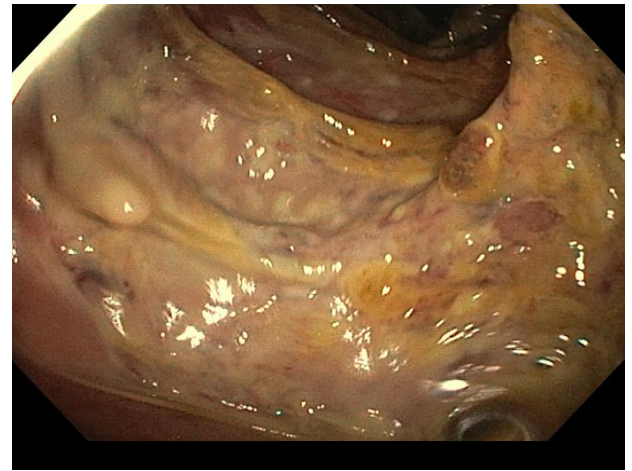Clinical Context:

70 years old patient with paralytic ileus and lesions DD ischemic related to a severe COVID-19 infection

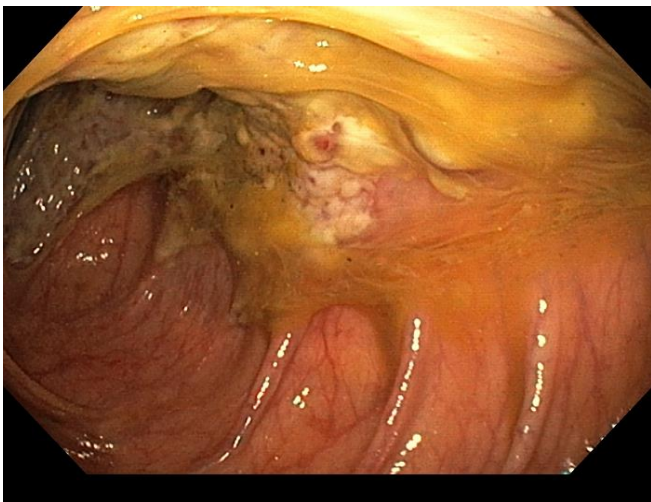




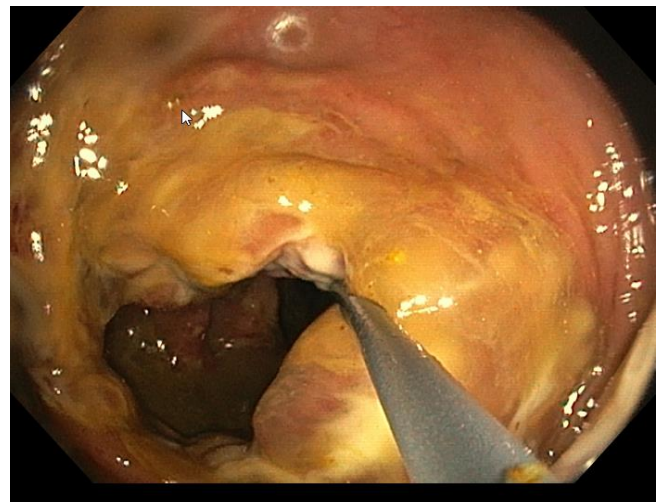
Colon ascendens



Colon ascendens



Colon transversum



Colon descendens

- Chan KH, Lim SL, Damati A, Maruboyina SP, Bondili L, Abu Hanoud A, Slim J. Coronavirus disease 2019 (COVID-19) and ischemic colitis: An under-recognized complication. *Am J Emerg Med.* 2020 May 27;S0735-6757(20)30432-0. doi: 10.1016/j.ajem.2020.05.072. Epub ahead of print. PMID: 32499176; PMCID: PMC7251350.
- Paul T, Joy AR, Alsub HARS, Parambil JV. Case Report: Ischemic Colitis in Severe COVID-19 Pneumonia: An Unforeseen Gastrointestinal Complication. *Am J Trop Med Hyg.* 2020 Nov 3. doi: 10.4269/ajtmh.20-1262. Epub ahead of print. PMID: 33146121.