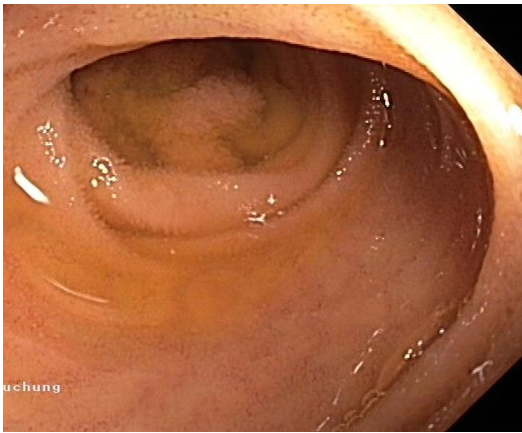


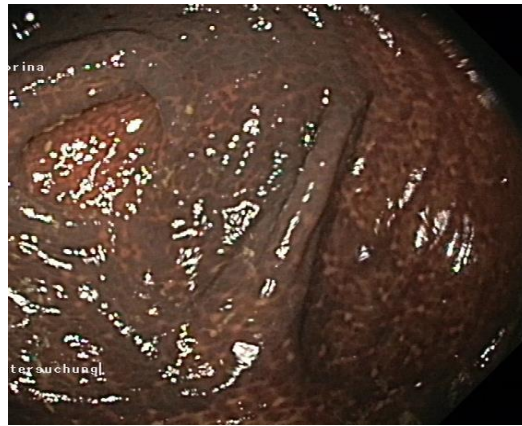
Clinical Context:

♀, 38 yo

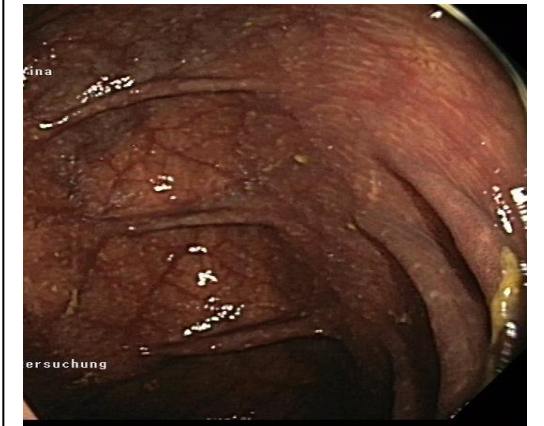- Mixed-type irritable bowel syndrome (diarrhea and constipation)
- Abuse of laxatives since childhood



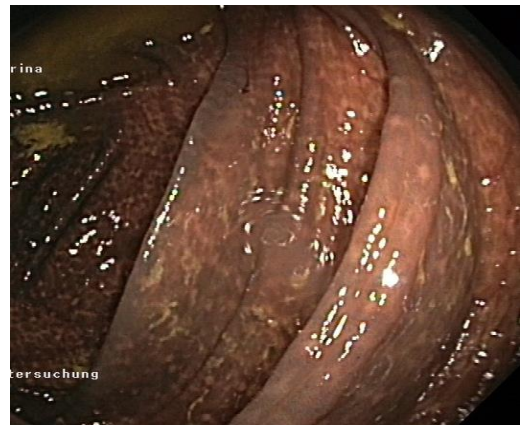Ileum



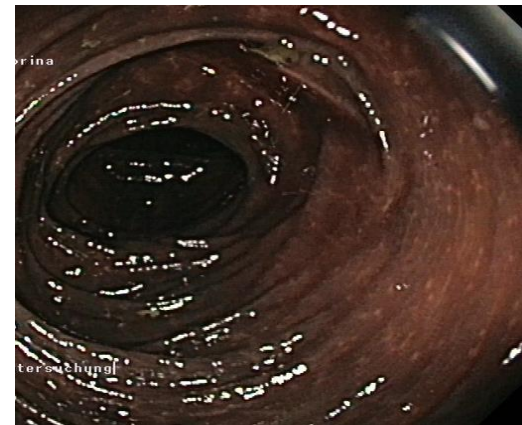
Caecum



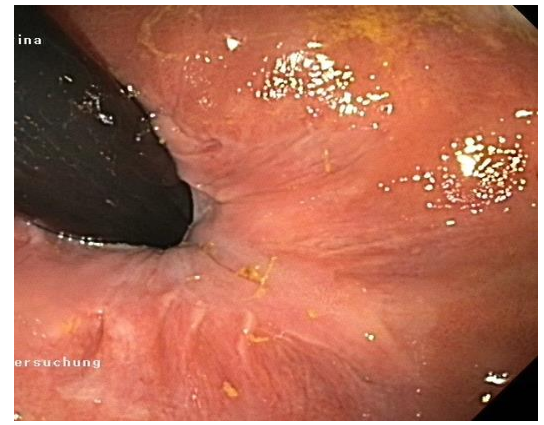
Colon Ascendens



Colon Transversum



Colon Descendens



Rectum Inversion