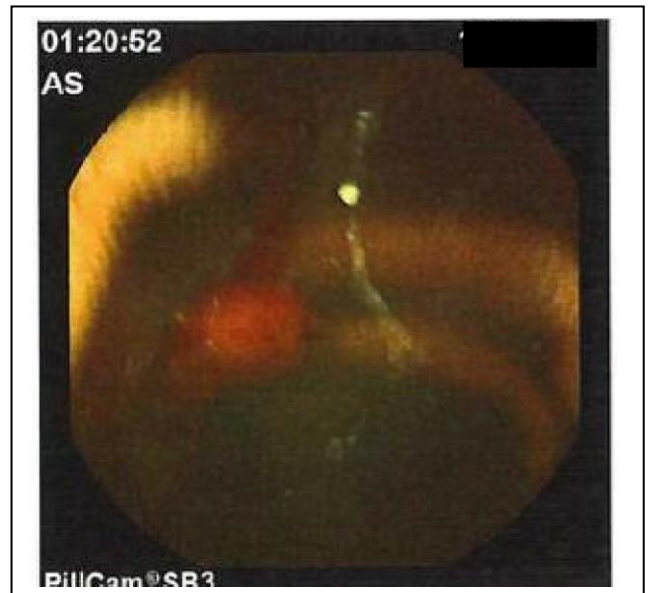
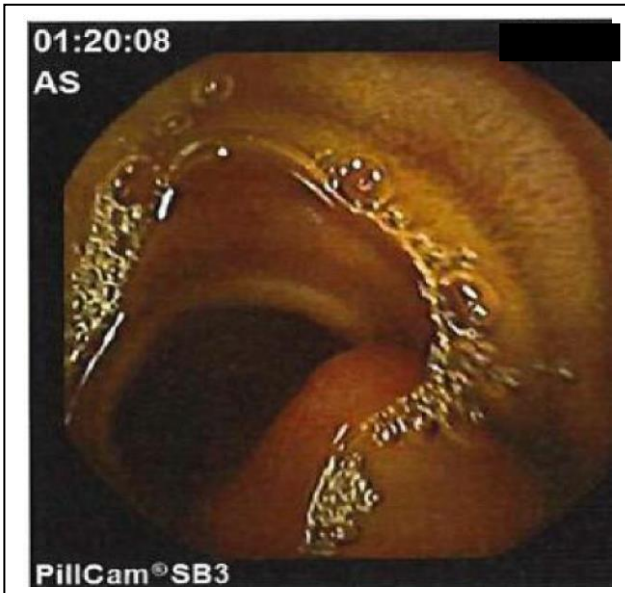
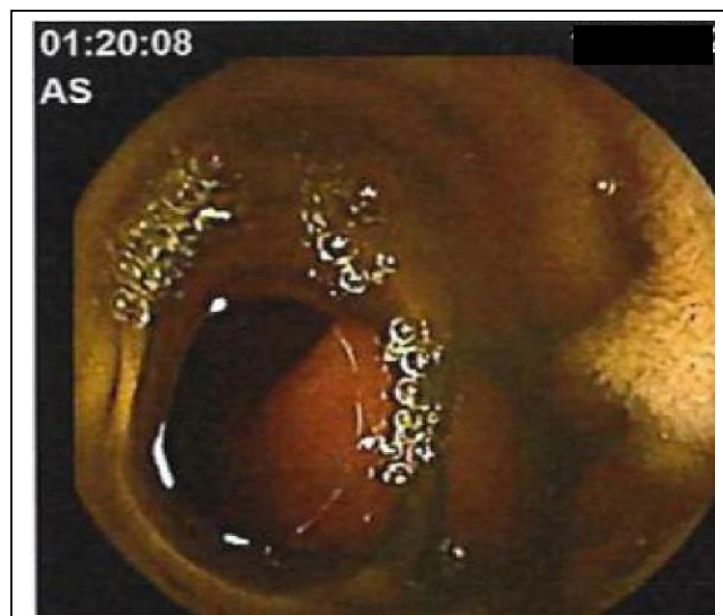Clinical Context:

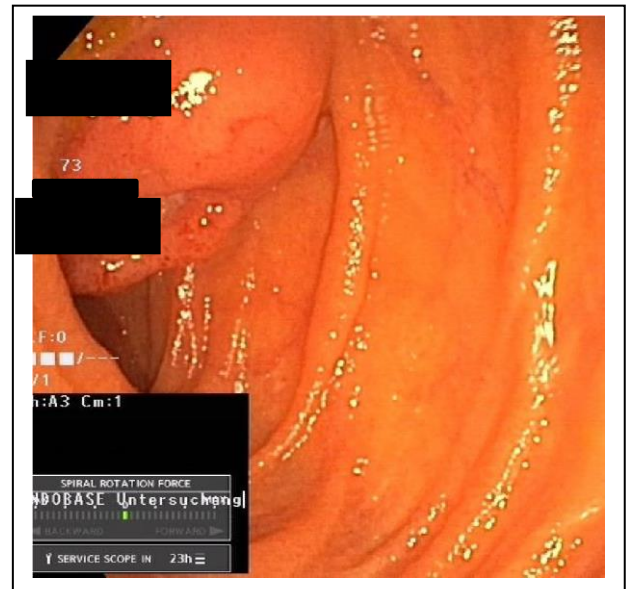
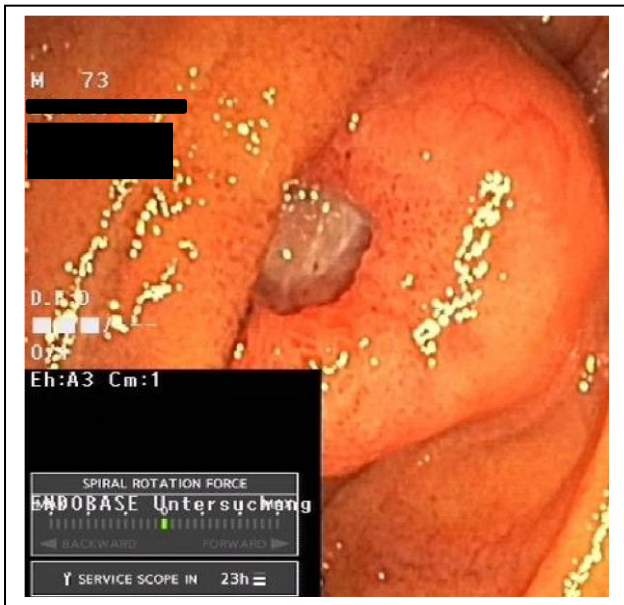♀ 73 yo

- Melena with anemia, Hb: 44 g/L (11.2020)
- Gastroscopy 07.12.20: no relevant findings
- Colonoscopy 08.12.20: sigmoidal diverticulosis, grade II hemorrhoids

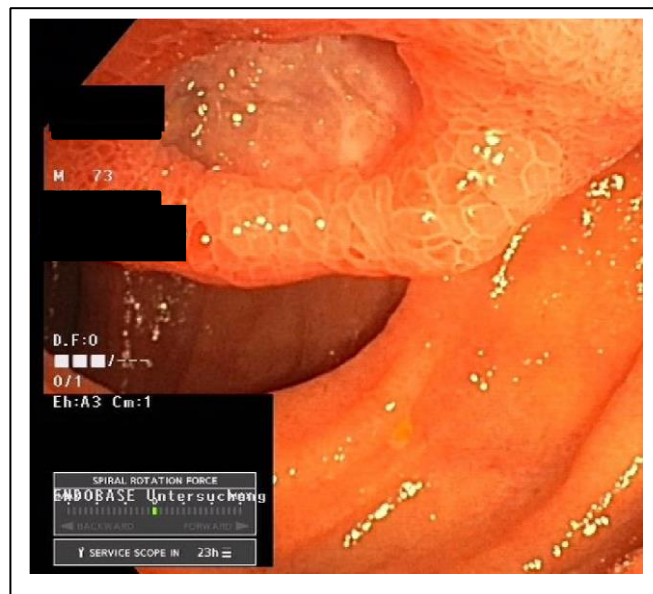

Videocapsule Endoscopy: polypoid lesion in the jejunum
with blood clot





22.04.2021 Spial enteroscopy: In the middle of the jejunum, large mass with central, fibrin-covered defect



- Histology 26.04.2021: gastrointestinal stromal cell tumor
- Treatment 05.05.2021: Laparoscopic central jejunum segment resection