



Guidelines for the diagnosis and management of intrahepatic cholangiocarcinoma

John Bridgewater¹, Peter R. Galle², Shahid A. Khan³, Josep M. Llovet^{4,5}, Joong-Won Park⁶, Tushar Patel⁷, Timothy M. Pawlik⁸, Gregory J. Gores^{9,*}

¹University College, London Cancer Institute, 72 Huntley St., London WC1E 6AA, UK; ²Department of Internal Medicine I, University Medical Center, Johannes Gutenberg University, Mainz, Germany; ³Hepatology and Gastroenterology Section, Department of Medicine, Imperial College London, UK; ⁴HCC Translational Research Laboratory, Barcelona-Clinic Liver Cancer Group, Institut d'Investigacions Biomèdiques August Pi i Sunyer, Hospital Clinic Barcelona, Catalonia, Spain; ⁵Mount Sinai Liver Cancer Program, Division of Liver Diseases, Icahn School of Medicine at Mount Sinai, New York, USA; ⁶Center for Liver Cancer, National Cancer Center, Goyang, Republic of Korea; ⁷Department of Transplantation, Mayo College of Medicine, Mayo Clinic, 4500 San Pablo Boulevard, Jacksonville, FL 32224, USA; ⁸Department of Surgery, Sidney Kimmel Cancer Center, Johns Hopkins University School of Medicine, Harvey 611, 600 N Wolfe Street, Baltimore, MD 21287, USA; ⁹Division of Gastroenterology and Hepatology, Mayo College of Medicine, Mayo Clinic, Rochester, MN, USA

Introduction

Cholangiocarcinoma (CCA) comprises a heterogeneous group of cancers with pathologic features of biliary tract differentiation, and is presumed to arise from the intra- or extrahepatic biliary tract. Two recent papers suggest these cancers may also arise directly from transdifferentiation of hepatocytes [1,2]. Gallbladder cancer is distinct from cholangiocarcinoma in epidemiology, pathobiology, clinical presentation and management, and should be considered a different form of biliary tract cancer [3]. On the basis of its anatomical origin, CCA is best classified anatomically as intrahepatic (iCCA), perihilar (pCCA), or distal (dCCA) CCA [4]. The incidence of iCCA appears to be increasing and may be as high as 2.1 per 100,000 person years in Western Countries [5]. iCCA may occur in patients with normal liver or with underlying liver disease, and in either clinical context usually is classified pathologically as an adenocarcinoma, although mixed hepatocellular – cholangiocarcinomas also occur, especially in chronic liver disease [6].

Given the increasing incidence of this complex and fatal disease, the growing recognition of iCCA as a distinct cancer, and the large number of recent publications on this disease, the International Liver Cancer Association (ILCA) governing board noted it was both timely and topical to develop practice guidelines on iCCA. These guidelines are largely based on a consensus of a multidisciplinary, geographically diverse writing committee using a data-supported approach, and subsequently reviewed by a separate Practice Guidelines committee of ILCA. The ILCA guidelines

committee employed an extensive PubMed search to broadly canvas the existing literature. Each author then wrote different sections of the manuscript relative to their expertise. All authors then reviewed and edited the manuscript to ensure objectivity and evidence-based recommendations. Finally an ILCA oversight committee reviewed the document, provided recommendations, and then additional edits were made to the document. Thus, a two-tiered integrated and interactive process was employed to generate the guidelines. These recommendations suggest preferred approaches to the diagnostic and therapeutic aspects of care, and are intended to be flexible, in contrast to standards of care, which should be supported by robust evidence-based data. Thus, the guidelines have two principal goals: (1) to provide physicians with pragmatic clinical recommendations; and (2) to identify areas of interest for future research, including suggestions for conducting clinical trials. The evidence and recommendations in these guidelines have been graded according to the Grading of Recommendations Assessment Development and Evaluation (GRADE) system, Table 1 [7]. The GRADE system classifies the evidence as high, moderate, low or very low quality. The strength of recommendation is either strong or weak based on the quality of underlying evidence, outcomes, and cost.

Epidemiology & risk factors

The incidence of cholangiocarcinoma varies substantially worldwide with the highest known rates in Northeast Thailand (>80 per 100,000 population) and much lower rates in the Western world, for example Canada (0.3 per 100,000) (Fig. 1) [8]. iCCA is the second most common primary liver cancer in humans, after hepatocellular carcinoma (HCC). Although the frequency of iCCA worldwide is considerably less than HCC, of note, several recent studies from around the world have reported rapidly rising rates of iCCA over the last few decades [9–11].

Keywords: Intrahepatic cholangiocarcinoma; Practice guidelines; Diagnosis and management.

Received 12 July 2013; received in revised form 22 January 2014; accepted 29 January 2014

* Corresponding author. Address: Mayo College of Medicine, Mayo Clinic, 200 First Street SW, Rochester, MN 55905, USA. Tel.: +1 507 284 0686; fax: +1 507 284 0762.

E-mail address: gores.gregory@mayo.edu (G.J. Gores).

Open access under CC BY-NC-ND license.



ELSEVIER

Table 1. Grading of evidence and recommendations (adapted from GRADE system) [7].

Evidence quality	Notes	Grading
High	Further research is very unlikely to change our confidence in the estimate of effect	A
Moderate	Further research is likely to have an important impact on our confidence in the estimate of effect and may change the estimate	B
Low	Further research is very likely to have an important impact on our confidence in the estimate of effect and is likely to change the estimate. Any change of estimate is uncertain	C
Recommendation	Notes	Grading
Strong recommendation warranted	Factors influencing the strength of the recommendation included the quality of the evidence, presumed patient-important outcomes, and cost	1
Weak	Variability in preferences and values, or more uncertainty: more likely a weak recommendation is warranted. Recommendation is made with less certainty, higher cost or resource consumption	2

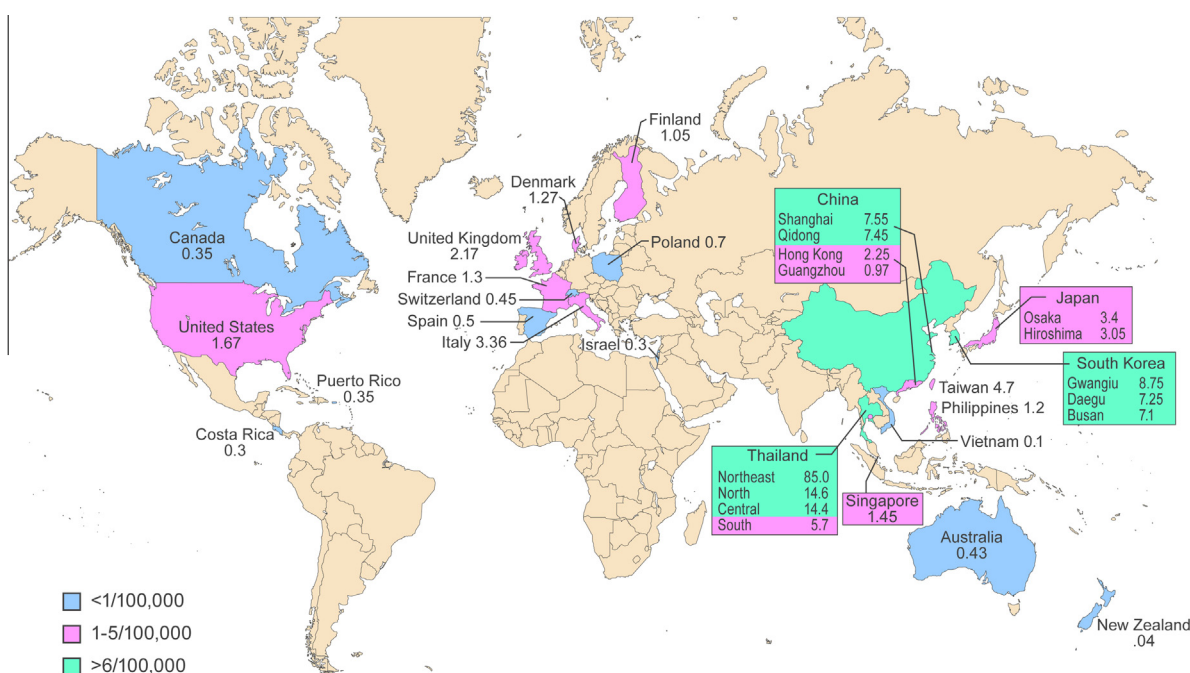


Fig. 1. Incidence of cholangiocarcinoma worldwide where reported.

Trends in iCCA rates worldwide

An increase in mortality rates from iCCA was concomitantly reported in studies from the US and the UK [12,13]. The study from the UK analyzed age standardized mortality rates (ASMR) per 100,000 population for hepatopancreatobiliary (HPB) tumors [12]. Between 1968 and 1996, there was a 15-fold increase in age specific mortality rates (ASPMR) from 0.1 to 1.5 per 100,000 population in ages 45 and above in both sexes. Since the mid-1990s, iCCA has become the most common cause of death from a primary liver tumor in England and Wales, overtaking HCC. Similar trends were found in incidence rates of this cancer in England and Wales [14]. A study from the US also reported a marked rise in both incidence and mortality rates from iCCA between 1973 and 1997, with an estimated annual percent change (EAPC) of 9.1% and 9.4% respectively [13]. Age-adjusted incidence rates of

iCCA in the US increased by 165% from 0.3 per 100,000 in 1975–1979 to 0.9 per 100,000 in 1995–1999 [10,11]. More recent studies from Italy and Germany also reported rises in iCCA. In Italy iCCA mortality rates increased from 0.2 to 5.9 per million between 1980 and 2003 [15] and in Germany iCCA mortality more than tripled between 1998 and 2008 [16]. Incidence rates of iCCA have also recently increased in Korea, with an annual percent change (APC) of 8% in males and 11% in females, between 1999 and 2005 [17].

Two studies examining international time trends in mortality rates using the World Health Organization’s (WHO) database found that ASMR for iCCA had risen in almost all countries across all continents, albeit at different rates [18,19]. The average global estimated annual percent change (EAPC) in ASMR for males was 6.9 ± 1.5, and for females 5.1 ± 1.0 [19]. In contrast to the aforementioned data, in Denmark between 1978 and 2002, incidence

Guidelines

rates of iCCA decreased from 1.3 to 0.5 per 100,000 people [20]. Why iCCA has decreased in Denmark in contrast to other countries is unknown.

Ethnic differences in iCCA rates

The reports so far described have found similar trends in iCCA rates in both sexes, with a slight male predominance overall (male to female ratio 1.2–1.5:1) [21]. Two studies, both from the US, have examined trends in iCCA rates based on ethnicity within geographically defined regions [22,23]. Both investigations, using data from the US Surveillance, Epidemiology, and End Results (SEER) database, noted significant racial and ethnic differences in iCCA rates. The age-adjusted prevalence of iCCA per 100,000 for males and females, respectively, for all races was 0.9 and 0.6; for Whites, 0.9 and 0.6; for Blacks, 0.5 and 0.2; and for Asian/Pacific Islanders was 1.3 and 0.8 [22,23]. iCCA prevalence was highest in Hispanics (1.2 per 100 000), and in contrast to the general male predominance, the prevalence among Hispanics was higher in females compared with males (1.5 vs. 0.9 per 100,000). Age-adjusted mortality rates for males and females were higher for American Indian/Alaska Native (1.3 per 100,000) and Asian Pacific groups (1.4 per 100,000) than for either Whites (0.8 per 100,000) or Blacks (0.7 per 100,000) [22]. However, mortality rates increased by over 3.5% per year for all ethnic groups except for American Indian/Pacific Islanders, in whom mortality rates decreased by 0.2% annually. The increase in mortality rates was greatest for Hispanic women aged between 40 and 49 years. In a separate study, iCCA incidence rates were similar for Black and White men (0.9/100,000), but higher for White women (0.6/100,000) compared to Black women (0.4/100,000) [23]. Although iCCA incidence increased among all groups, approximately doubling between 1976 and 2000, the increase was greatest for Black men (138.5%), followed by White men (124.4%), White women (111.1%), and Black women (85.7%) [23].

Are the reported rates of changing CC incidence accurate?

There is an evolving discussion in the literature about whether iCCA incidence is genuinely increasing. The possibility that rising iCCA rates may reflect improved detection, for example due to improvements in diagnostic techniques over the past few decades, has rarely been investigated. One US study addressed this question by examining SEER data between 1975 and 1999 [10,11]. iCCA incidence increased by 165%, during which time no significant changes were found in the proportion of patients with unstaged cancer, localized cancer, microscopic confirmation, or with tumor size <5 cm, suggesting a true increase in iCCA rather than earlier or improved diagnosis [10,11]. Further studies looking at this issue are warranted, particularly given that CCA can be notoriously difficult to accurately diagnose [24]. When iCCA presents at an advanced stage, which is common, it can be impossible to determine the anatomical origin, and the histological sub-type, which can result in misclassification as a non-hepatobiliary upper gastrointestinal tract adenocarcinomas [21]. A significant issue is the lack of histopathological confirmation in a substantial percentage of iCCA cases in most cancer registries worldwide, which makes it impossible to definitively establish the true epidemiological behavior of iCCA [25].

Another confounding factor in assessing CCA epidemiology is that of potential misclassification under serially evolving editions

of the World Health Organization's (WHO) International Classification of Disease (ICD) coding systems. Alongside the main ICD coding system is the ICD coding system for Oncology (ICD-O), which was introduced in 1979 and assigns two codes dependent upon a tumor's anatomical topography and morphology (based on histology) [26]. Thus there are separate codes for topography and histology. Both ICD and ICD-O are updated every few years and codes are altered. Furthermore, these changes are adopted by different countries' cancer registries at different times. There is increasing consensus that iCCA, pCCA, and dCCA are three distinct entities due to their differing epidemiology, pathobiology, clinical presentations, and management [4]. The most common type of CCA encountered in clinical practice is perihilar, historically referred to as a Klatskin tumor [27]; the definition of pCCA includes tumors above the junction of the cystic duct up to and including the second biliary branches of the right and left bile ducts that reside within the hepatic parenchyma [4,28]. However, CCA are only coded as either intra- or extrahepatic and a separate ICD topography code for perihilar tumors does not exist. pCCA are topographically extrahepatic and should have historically been coded as such [24]. However, the first edition of the ICD for Oncology (ICD-O) did not specify whether pCCA should be classified as intra- or extrahepatic. The second edition of ICD-O assigned Klatskin tumors a unique histology code for the first time, but this was cross-referenced to the topography code for intrahepatic (IHBD) rather than extrahepatic bile duct tumors (EHBD). Under the third and current edition of ICD-O-3, Klatskin tumors can be cross-referenced to either IHBD or EHBD. Thus, hilar/Klatskin tumors may have been misclassified under all versions of the ICD-O [24,29].

The impact of this misclassification on site-specific CCA incidence rates was examined using US SEER data [29]. Between 1992 and 2000, when SEER used ICD-O-2, 91% of pCCA were incorrectly coded as iCCA, resulting in an overestimation of iCCA by 13%. However, they found that the overall proportion of tumors classified as Klatskin or pCCA in the SEER database was low, at only 8%. This was a surprising finding given that in published studies, as well as clinical experience, pCCA tumors account for the majority of all CCA [27]. A study of CCA incidence in East and South-eastern Asia also found that the proportion of Klatskin/pCCA tumors among CCA was less than that reported in clinical settings [30]. Furthermore, coding practices for pCCA tumors differed between cancer registries in Asia.

A more recent study compared the impact of ICD coding changes on CCA incidence rates between 1990 and 2008 in England, Wales, and the US [24]. Coding practices by all national cancer registries in England and Wales were also assessed via questionnaire [24]. In the US, the age standardized incidence rate (ASIR) for iCCA rose from 0.6/100,000 to 0.9 between 1990 and 2001, then fell sharply before plateauing at 0.6 by 2007. ASIR for extrahepatic bile duct tumors remained stable at around 0.8/100,000 population until 2001, then increased to 1.0 by 2007. In England and Wales, between 1995 and 2008, the vast majority of pCCA tumors were coded as intrahepatic. This was also the case in the US until 2001, when the situation was reversed and subsequently most pCCA tumors were coded as extrahepatic. Of note, US trends in intra- and extrahepatic tumors began to reverse when the switch from ICD-O-2 to ICD-O-3 occurred in 2001. In the UK, the switch to ICD-O-3 only occurred in 2008, the end of the study period. Furthermore, in England and Wales, only 1% of CCA were reportedly pCCA, which is clearly a

massive underestimation. Cancer registries in England and Wales stated they would not code a CCA described as hilar with the designated Klatskin histology code, even though they are the same entity, as the term hilar is not in the ICD classification. In the UK, the term hilar is used rather than Klatskin and most cancer registries confirmed that if the tumor site is unspecified, or simply says hilar or perihilar, the CCA would be coded as intrahepatic. Thus coding misclassification is likely to have skewed CCA registration to an intrahepatic site, thereby contributing to previously reported rises in iCCA, at least in England and Wales and likely in other countries [24]. Given CCA is relatively uncommon in most countries, subtle misclassifications can substantially affect reported rates [21].

In conclusion, close surveillance of international incidence trends for all hepatobiliary tumors is recommended. An accurate and consistent classification practice for CCA is needed internationally considering the potential misclassification of pCCA. We suggest bile duct cancers could be sub-classified as iCCA, pCCA, or dCCA with the term Klatskin being omitted altogether [4,31,32]. The terms intrahepatic vs. extrahepatic are unhelpful in this situation. Importantly, however CCA are classified, their overall incidence seems to be increasing and the reasons for this need to be investigated [24].

Recommendations 1

Recommendations

- CCA should be sub-classified as intrahepatic (iCCA), perihilar (pCCA), or distal (dCCA) where iCCA arises within the liver parenchyma. The terms Klatskin and extrahepatic are discouraged

Recommendation A1

Suggestions for future studies

- Overall the incidence of iCCA seems to be increasing globally and the reasons for this need to be further investigated

Risk factors for iCCA

Cholangiocarcinogenesis is likely to be a multifactorial process [33]. Significant geographical and ethnic variations in the epidemiology of CCA, globally and within the same geographical regions, likely reflect differences in genetic, environmental and/or cultural predispositions to the disease. Several risk factors for CCA have been identified, however in the vast majority of cases the disease is sporadic and known or suspected risk factors are not present [9,21]. Unfortunately, studies examining potential risk factors often do not differentiate between iCCA, pCCA or dCCA and so the effects of different risk factors on CCA sub-types are unclear [21]. Long established risk factors for CCA, such as hepatobiliary flukes, primary sclerosing cholangitis (PSC), biliary tract cysts, hepatolithiasis and toxins are associated with chronic biliary inflammation and increased cellular turnover [33]. More recently recognized risk factors for iCCA are similar to those known for HCC, such as cirrhosis, chronic hepatitis B and C, obesity, diabetes, and alcohol [34]. However, the prevalence of these risk factors is much lower for iCCA than for HCC. Suspected risk

factors include inflammatory bowel disease, smoking, and genetic polymorphisms. Many known risk factors for CCA such as PSC, are associated with pCCA or dCCA, and will not be reviewed here.

In regions of the world with highest CCA incidence, such as Northeastern Thailand, where CCA is the most common cancer and a major cause of mortality, the hepatobiliary flukes *Opisthorchis viverrini* and *Clonorchis sinensis* are strongly associated with the development of CCA. In 2009, these flukes were classified as group 1 human carcinogens for CCA by the WHO's International Agency for Research on Cancer. Human infection occurs via eating raw/undercooked freshwater fish; subsequently, the flukes inhabit the biliary tree leading to chronic irritation [35]. Several case-control studies and a recent meta-analysis have shown a strong association between liver flukes and CCA, with odds ratios (OR) of up to 27 [36]. Consumption of nitrosamine-contaminated food may be an additional risk factor [37,38]. Apparently approximately 40% of CCA associated with flukes are iCCA.

Choledochal cystic diseases, such as Caroli's disease, are uncommon inherited abnormalities of the pancreatobiliary ducts which result in reflux of pancreatic enzymes, cholestasis, and biliary inflammation [39]. These diseases, which are more common in Asian than Western countries, are strongly associated with CCA, with an overall lifetime risk ranging from 5% to 30% [39,40]. Compared to Western peoples, Asians have a higher prevalence of choledochal cysts and also a higher incidence of CCA, up to 18% compared to 5% lifetime risk of CCA [39,41,42]. Types I (solitary, extrahepatic) and IV (intra- plus extrahepatic) bile-duct cysts have the greatest predisposition to CCA [39]. CCA incidence in these patients increases with age, the average age at CCA diagnosis is 32 years [39]. A recent Korean case-control study confirmed a strong association between bile duct cysts and iCCA, with an OR of 10.7 [43]. A US SEER-based study reported strong associations between bile duct cysts and increased risk of iCCA (OR 36.9) and extrahepatic CCA (OR 47.1) [44].

Calculi in the biliary tree, with or without concomitant parasite infection, are a known risk factor for CCA. For reasons which are unknown, hepatolithiasis is far more common in Southeast Asia than the West (up to 20% in countries such as Thailand, compared to 2% in the US) [21]. Case-control studies have found high ORs for developing iCCA with hepatolithiasis, up to 50 in Korea [43], 6 in China [45], and 7 in Italy [46]. In a hospital based case-control study from China; smoking, a family history of cancer, and a greater than 10 year duration of symptoms were independent risk factors for iCCA development in patients with hepatolithiasis [47].

Case-control and cohort studies from Denmark, Japan, US, and Korea have reported cirrhosis, of any aetiology, as an independent risk factor for iCCA with risk estimates ranging between 5 and 14 [43,44,48–50]. A recent meta-analysis of seven case-control studies, including data on almost 400,000 patients, found that cirrhosis was associated with an overall OR of 23 for iCCA [34]. A series of recent case-control studies from Asia, the US and Europe have reported a strong association between chronic viral hepatitis and iCCA [36,43–46,50–53]. However, studies report conflicting findings as to whether HBV or HCV or both viruses were associated with CCA. Risk estimates for HBV as a risk factor for iCCA varied between 2.3 (Korea) [43,53] and 28.6 (US) [53]. In a recent meta-analysis, eight case-control studies investigating HBV as a risk factor for iCCA, including data from 1991 to 2008 and

Guidelines

encompassing a total study population of almost 295,000 patients were selected [34]. The meta-analysis indicated that overall, HBV was associated with iCCA with a combined OR of 5.5. There were no significant differences between studies from Eastern or Western countries. A retrospective case-control study from Taiwan reported 38% of all iCCA were Hepatitis B surface antigen positive (OR 5.0) and 13% were seropositive for HCV (OR 2.7) [54]. The mean age of iCCA patients with HBV was 9 years younger than iCCA patients with HCV. Similarly, a recent study from China found that, compared to HBV seronegative patients with iCCA, HBV seropositive iCCA patients were younger, more commonly male, and had a higher incidence of raised serum alpha-fetoprotein level and cirrhosis [55]. Regarding HCV as a risk factor for iCCA, risk estimates in individual studies varied between 2.6 (US) [51] and 9.7 (Italy) [46]. In a meta-analysis HCV was associated with iCCA, with an OR of 4.8 [34].

Obesity is increasingly linked to several cancers. In a UK study, a body mass index of >30 was significantly associated with biliary tract cancer, but this included all CCA types as well as gallbladder cancer [56]. A recent US study of SEER data between 1993 and 2005 reported that metabolic syndrome was significantly associated with an increased risk of iCCA (OR 1.6) [57]. A combined analysis of two US and one Danish study, investigating obesity as a risk factor for iCCA, revealed an overall OR of 1.6 [34]. Individual studies report conflicting results regarding diabetes as a risk factor for iCCA. Three large population based case-control studies, two US [44,48], and one UK [56], reported a significant positive association between diabetes and CCA, with risk estimates between 1.5 and 2.0. Conversely, a population based case-control study in Denmark [44], and three hospital-based studies from China [45], Japan [50], and the US [53] did not show a significant association. However, a meta-analysis found diabetes was associated with an overall OR of 1.9 for iCCA [34].

Individual case-control and cohort studies, including those already referenced, have reported contrasting findings regarding an association between alcohol use and CCA. In the recent meta-analysis alcohol excess was associated with an overall OR of 2.8 for iCCA [34]. In contrast to alcohol, the data linking smoking to iCCA are either negative or demonstrate a weak association [21]. A meta-analysis of these eight studies estimated an overall OR of 1.3 with confidence intervals of 0.95–1.8 [34]. However, significant heterogeneity between studies was noted, as well as inconsistencies regarding parameters of smoking frequency or

duration. Further data are required to clarify if smoking is a genuine risk factor for iCCA.

Host genetic polymorphisms

Given that only a minority of people with any of the established risk factors for CCA get the disease, and given the significant ethnic and geographical variations in CCA incidence, it is likely that host genetic factors play a role in CCA predisposition [33]. There is some evidence for this from several case-control studies, which suggest that variations in genes coding for a number of enzyme systems may be associated with increased CCA risk (Table 2). These studies have involved relatively small numbers, with CCA cases ranging between 50 and 200, and CCA sub-types are usually unspecified. Larger genetic studies are required to shed further light on this important area.

Recommendations 2

Recommendations

- iCCA has similar risk factors to HCC, including cirrhosis, chronic viral hepatitis, alcohol excess, diabetes, and obesity, which suggests common pathobiological pathways to all primary liver parenchymal tumors.
Recommendation A1

Suggestions for future studies

- Further investigations regarding genetic polymorphisms and the risk of iCCA are recommended

Molecular pathogenesis

Overview

The molecular pathogenesis of iCCA is a complex issue involving several signal transduction pathways and molecular events (Fig. 2) [58,59]. iCCA likely results from malignant transformation of cholangiocytes, and in a subset of cases from progenitor cells, although this paradigm has been challenged [1,2]. Recent data

Table 2. Host genetic polymorphism associated with cholangiocarcinoma.

Gene product	Abbreviation	Protein function	[Ref.]
5,10-Methylenetetrahydrofolate reductase	MTHFR	Involved in folate metabolism and DNA methylation	[223]
Thymidylate synthase	TS	Associated with DNA repair	[223]
Glutathione S-transferases	GST01	Family of detoxification enzymes	[224]
Multidrug resistance-associated protein 2	MRP2/ABC2	Biliary transporter involved in clearing biliary toxins	[225]
ATP8B1	FIC1	Biliary transporter involved in trafficking phosphatidylserine in cellular membranes	[226]
Natural killer cell receptor in PSC patients	NKG2D	Role in activating NK cells, key for tumor surveillance	[227]
X-ray repair cross-complementing group 1	XRCC1	Involved in DNA repair	[228]
Prostaglandin-endoperoxide synthase 2/cyclooxygenase-2	PTGS2, COX-2	An inflammatory mediator	[229]
Heterozygosity for the alpha1-antitrypsin Z allele		A protease inhibitor which protects against pro-inflammatory enzymes	[230]

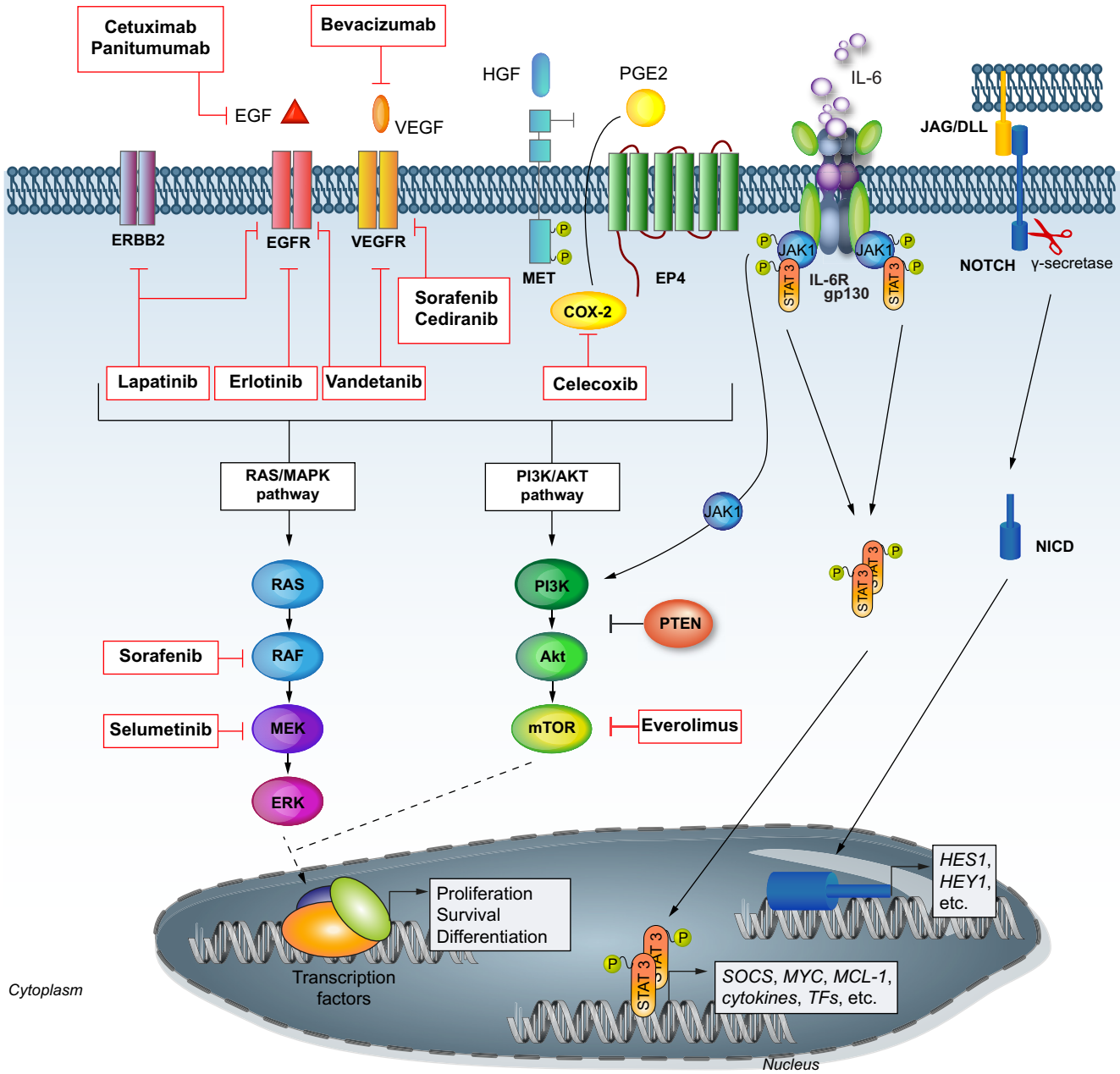


Fig. 2. Signaling pathways and molecular therapies in intrahepatic cholangiocarcinoma. Adapted by permission from McMillan Publishers Ltd.: Oncogene [59], Copyright (2013).

indicate common genomic traits between iCCA and HCC, supporting the hypothesis of common cell ancestors in specific molecular subclasses: (1) Transcriptome analysis suggests that the poor prognostic subclass of iCCA shares genomic traits and signatures of poor prognosis of HCC [58,60,61], which are associated with stem-like molecular signatures [62,63]; (2) iCCA and HCC share common copy number variations including gains (1q, 8q, and 17q) and losses (4q, 8p, 13q, and 17p) of arms and high-level amplifications of 11q 13 [58,60,64]; and (3) iCCA shares dominant risk factors associated with HCC development, including cirrhosis, HBV and HCV infections, and metabolic syndrome due to diabetes and/or obesity [34,57].

Genetic alterations in iCCA

A discrete number of mutations, chromosomal aberrations, deregulated signaling pathways, and epigenetic changes have been reported in iCCA.

Mutations

Activating mutations of *KRAS* represent one of the most frequent genetic mutations found in iCCA (5–54%) [58,60,65,66]. *KRAS* gene has been shown to be a bona fide oncogene inducing iCCA in genetically engineered mouse models [67], and these

Guidelines

mutations have been associated with a more aggressive phenotype [60]. Loss-of-function mutations of *TP53* occur in 20% of cases, and have been proven oncogenic in experimental models of iCCA [68,69]. *BRAF*, *NRAS*, *PI3K*, *EGFR*, and *MET* mutations are rare events involving <5% of cases [58,60,70]. Recently, mutations in isocitrate dehydrogenase 1 (*IDH1*) and 2 (*IDH2*) have been identified in 10–23% of 340 iCCA [71,72]. These mutations co-occurred with *TP53* mutations and were associated with DNA hypermethylation [72]. There is no reported study assessing whole-genome sequencing in iCCA, and the sole data available include eight cases of liver fluke-related CCAs [73].

Copy number variations

There are only a few studies reporting chromosomal imbalances in iCCA [58,74–78]. Five studies investigated copy number variations (CNV) performing comparative genomic hybridization (CGH) in 98 patients [74–78] and one study used single nucleotide polymorphism (SNP) arrays in 149 patients [58]. The main findings of these studies included frequent chromosomal gains on 8q, 17q, and 20q and deletions on 3p (60%), 4q, 9p, and 17p. The one study using SNP array technology [58] identified high-level amplifications (e.g., 1p31, 11q13) and focal deletions (e.g., 9p21, 14q22) in 4–12% of cases, pinpointing candidate regions harboring novel oncogenes and oncosuppressors.

Protein fusions

Fusions including the kinase domain of *FGFR2* have been recently reported [79]. This observation has been confirmed by a recent study from Japan coupled with functional studies in cell culture [80]. Moreover, several groups have similar observations (unpublished observations).

Epigenome changes

Epigenetic silencing through promoter hypermethylation along with miRNA deregulation have been described in a few studies [63,81]. Single-gene studies define common alterations in iCCA: hypermethylation of *p16^{INK4A}* in 18–83% of cases [82], *SOCS-3* in 88% [83], *RASSF1A* in 49% [75], and *p14ARF* in 25% [84]. At the same time, a cluster of 38 miRNAs was identified as markedly deregulated in iCCA and some of them were associated with aberrant signaling pathways (e.g., HGF/MET, IL-6/STAT-3) [81]. Amongst all miRNA deregulated, a link between miR-200c signaling, NCAM activation/stem cell gene expression trait and poor prognosis has been proposed [63]. Recent papers have been published assessing mutations in various populations with iCCA [73,85]. These studies highlight the role of chromatin modifiers especially *BAP1* in the genetic pathogenesis of this disease [85,86]. Thus, epigenetic alterations appear to play a dominant role in this disease.

Signaling pathways activated in iCCA

Several pathways have been found to be deregulated in iCCA, including inflammatory, cell cycle, and growth factor signaling pathways (Fig. 2). Although they contain potential drivers of carcinogenesis, to date no oncogenic addiction loop has been documented.

IL6-STAT3 pathway

Inflammation has been closely linked to an increased risk of iCCA. Overall, JAK/STAT signaling activation occurs in 50% of iCCA, and may affect more than 70% of the iCCA inflammation subclass [58]. In particular, IL-6 is an important oncogenic player in the growth of malignant cholangiocytes [83,87,88] and its over-expression may be a consequence of the epigenetic silencing of *SOCS-3*, the inhibitor of cytokine signaling [83,89].

EGFR signaling

Members of the EGFR family have been implicated in iCCA pathogenesis, and over-expression of EGFR (10–32%) and HER-2/neu have been reported in iCCA patients [90–92]. Amplifications and/or mutations of EGFR or HER-2 are very rare in iCCA. Aberrant EGFR phosphorylation activates MAPK/ERK and p38, which in turn increases COX-2.

Hepatocyte growth factor/Met signaling

C-Met, the tyrosine kinase receptor for hepatocyte growth factor (HGF), is over-expressed in iCCA (12–58%) [93,94]. Cross-talk between activation of EGFR family members, particularly HER-2, with c-Met pathways has been described in experimental models and in human studies [94,95].

Molecular classification of iCCA

Molecular stratification can be based on biomarkers as predictors of response to targeted drugs or biomarkers as prognostic factors. Few molecular subclasses have been adopted in management guidelines, and they are typically based upon biomarker predictors of treatment response. This is the case of amplification of Her2/neu and responders to trastuzumab in breast cancer [96], EGFR mutational status or ALK status and response to erlotinib and crizotinib, respectively, in non-small cell lung cancer [97,98], and B-RAF mutations to identify responders to B-RAF inhibitors in melanoma [99]. No such case has been described in iCCA.

Recent advancements have been made in defining molecular subclasses in iCCA based on whole-transcriptome analysis and other biological parameters [58–61,63,100,101]. The first comprehensive study included 104 cholangiocarcinoma cases – including iCCA, pCCA, and dCCA – and described two molecular subclasses, one of which was associated with poor prognosis and activation of receptor tyrosine kinases (RTKs), including EGFR, ERBB2, and MET [60]. An integrative genomic study of 149 iCCA identified two molecular subgroups, inflammation and proliferation, with distinct genomic profiles and clinical outcomes [58,59]. The inflammation subclass (40%) showed an enrichment of inflammation and cytokine pathway signatures, over-expression of IL6, IL10, and IL17 and constitutive activation of STAT3. The proliferation subclass (60%) was characterized by enrichment of activated oncogenic pathways including RAS/MAPK and MET, high-level DNA amplifications at 11q13, deletions at 14q22.1 and signatures of poor clinical outcomes. Further independent validation of iCCA subclasses is needed prior to adoption as stratification factors in iCCA guidelines.

Recommendations 3

Recommendations

- Signaling pathways, drivers of carcinogenesis, and potential targets for therapies in iCCA include KRAS/MAPK, EGFR, IL-6/STAT, IDH1/2, FGFR2 and MET signaling. No oncogenic addiction loops have been described so far

Recommendation C1

- Molecular classification of iCCA based on gene signatures or molecular abnormalities is not ready for clinical application

Recommendation C1**Suggestions for future studies**

- Future studies should focus on integrative genomic analysis studies combining genetic alterations with pathway identification, validating the use of genetic biomarkers to direct therapy, and further genetically stratifying patients with iCCA

Clinical diagnosis of iCCA*Clinical presentation*

The clinical presentation of iCC is non-specific and insufficient to establish a diagnosis. Patients with early stage disease are usually asymptomatic. At more advanced stages, patients may present with weight loss, malaise, abdominal discomfort, jaundice, hepatomegaly, or a palpable abdominal mass. Biliary tract obstruction occurs infrequently with iCCA. Tumor-related fever may rarely occur, although night sweats are common in advanced disease. Increased cholestasis and a declining performance status may occur in patients who develop CCA. CCA should be considered in patients with underlying hepatolithiasis or PSC with worsening performance status, unexplained loss of weight, or failure to thrive.

Pathologic diagnosis

A pathological diagnosis of iCCA is based on the WHO classification of biliary tract cancer showing an adenocarcinoma or mucinous carcinoma [102]. The most common histological findings of an iCCA are those of an adenocarcinoma showing tubular and/or papillary structures and a variable fibrous stroma [103–107]. Although it has been proposed that the diagnosis of iCCA can be made based upon a combination of clinical presentation, laboratory analysis, and radiologic evaluation, pathological diagnosis is required for definitive diagnosis in most patients, particularly those with cirrhosis and small hepatic mass lesions as radiographic studies are nonspecific [108,109]. Pathological diagnosis is recommended for all patients who will be undergoing systemic chemotherapy or radiation therapy, or enrolling in a therapeutic clinical trial.

The sensitivity of liver biopsy for pathological diagnosis will depend upon location, size, and operator expertise. Core biopsies are required for definitive diagnosis. Although a positive liver biopsy will establish a diagnosis, a negative biopsy does not exclude it because of the potential for sampling error. Tumor

seeding can occur with percutaneous biopsy but the risk is not well defined.

iCCA needs to be distinguished from benign biliary lesions such as peribiliary glands, reactive ductular proliferation, biliary microhamartomas (von Meyenburg complexes) and bile duct adenomas (peribiliary tract hamartomas), particularly in the presence of inflammation which can result in reactive cellular atypia [110]. The histological appearance of iCCA is similar to that of metastatic adenocarcinoma arising from extrahepatic primary tumors and especially those of foregut origin such as lung, pancreas, esophagus, and stomach [110]. The differentiation of iCCA from metastatic adenocarcinoma cannot be readily ascertained on histological examination. Differentiation between iCCA and mixed HCC tumors may require evaluation of specific markers of hepatocellular or progenitor cell features such as Hep-Par-1, GPC3, HSP70, glutamine synthetase, EpCAM, and CK19. CK19 positivity is not specific for iCCA. The expression of cytokeratin 7 and cytokeratin 20 may be helpful to establish a biliary origin [111,112].

Diagnosis using imaging studies

iCCA may be incidentally detected by cross-sectional imaging performed for other reasons. Imaging features of iCCA are often suggestive of the diagnosis but not definitive enough to obviate the need for a biopsy. On CT scanning, the typical appearance is that of a hypodense hepatic mass in the unenhanced phase with irregular margins, peripheral rim enhancement in the arterial phase, and progressive hyperattenuation on venous and delayed phases [113]. CT can also detect the level of biliary obstruction, capsular retraction or hepatic atrophy. Dynamic CT scanning can help distinguish between iCCA and HCC. Up to 81% of iCCA are characterized by a progressive contrast uptake from the arterial to the venous and especially in the delayed phase. This effect may reflect fibrosis which is slow to enhance but retains the intravenous contrast agent. In contrast, HCC is characterized by rapid enhancement during the arterial phase and relative wash-out (hypoattenuation) in the venous or delayed phases. However, some small mass-forming iCCA are arterially enhancing and may mimic hepatocellular carcinoma [114,115].

On MRI, iCCA appear hypointense on T1-weighted and hyperintense on T2-weighted images [116–118]; T2-weighted images may also show central hypointensity corresponding to areas of fibrosis. Dynamic images show peripheral enhancement in the arterial phase followed by progressive and concentric filling-in of the tumor with contrast material. Pooling of contrast on delayed images is indicative of fibrosis and suggestive of an iCCA in the right clinical setting. MRI with cholangiopancreatography (MRI/MRCP) can be helpful to visualize the ductal system and vascular structures and thereby to determine the anatomic extent of tumor.

Fluorodeoxyglucose positron emission tomography (FDG-PET scan) can detect cholangiocarcinomas. Mass forming iCCA as small as 1 cm can be detected with a reported sensitivity of 85–95%. However FDG-PET is less useful for infiltrating tumors [119–121]. There is limited clinical utility of CT/PET for diagnosis of iCCA in the liver when CT or MRI imaging has been performed [122].

On ultrasonography, iCCA appears as a hypoechoic mass and may be associated with peripheral ductal dilatation. These features are not specific. Hyperenhancement on contrast enhanced ultrasound can identify tumors with increased density of cancer cells but lacks specificity for iCCA [123,124].

Guidelines

A presumed diagnosis of iCCA can be made on radiological criteria such as venous phase contrast enhancement on dynamic imaging in the absence of other extrahepatic primary malignancies and cirrhosis. Radiological criteria are insensitive for the diagnosis of iCCA in the presence of cirrhosis. Radiological studies cannot reliably differentiate between scirrhous HCC and iCCA, or metastatic adenocarcinoma and iCCA [125].

Tumor markers

Tumor markers in serum or bile are not specific for iCCA but may be of diagnostic value. Current tumor markers such as Carbohydrate Antigen (CA) 19-9 and carcinoembryonic antigen have significant overlap with other benign diseases and low sensitivity for early stage disease which limit their use for diagnosis. The sensitivity and specificity of CA 19-9 for iCCA is only 62% and 63%, respectively. However, patients with unresectable CCA typically have significantly higher CA 19-9 levels compared with patients with resectable CCA [126]. Other studies have noted that preoperative CA 19-9 values greater than 100 U/ml were also associated with worse recurrence-free survival after surgical resection [127]. Bile duct obstruction or acute cholangitis may affect CA 19-9 levels. In the setting of bile duct obstruction, CA 19-9 levels should be reassessed after biliary intervention/drainage since the half-life of CA 19-9 is one to three days. Other serum markers, such as serum cytokeratin-19 fragment (CYFRA 21-1) and CA-242, have been reported to have higher specificities than CA 19-9 for iCCA in a limited number of studies, but are not in routine use [128].

Genetic biomarkers

Recent studies have identified mRNA and non-coding RNA expression that are associated with iCCA [61,129–131]. At present there is insufficient evidence to support the use of gene testing in blood or tissues for these genes, either singly or in combination, for the diagnosis of CCA.

Assessment of disease extent

Radiological studies are necessary for assessment of the extent of local-regional, or distant spread, staging, and resectability. Invasion into the portal vein or hepatic artery, and volumetric assessment of uninvolved liver are important determinants of resectability. Radiographic studies have a limited ability to determine the extent of intraductal tumor spread and resectability, particularly for the periductal infiltrative type of iCCA.

Color Doppler duplex US can identify vascular invasion, encasement, or occlusion of the portal vein and the hepatic artery. In one report, preoperative US detected 13 of 16 cases of liver tumors involving the hepatic vein with 81% sensitivity and 97% specificity, and an 87% positive predictive value [132]. In another study, preoperative US detected 38 of 41 patients with CCA and portal vein involvement at surgery, with 93% sensitivity, 99% specificity, and 97% and 98% positive and negative predictive values, respectively [133]. These results were comparable to those found by angiography with computed tomographic arterial portography which identified 37 of 41 involved portal veins with 90% sensitivity, 99% specificity, 95% positive predictive value, and 97% negative predictive value.

FDG-PET cannot be used to diagnose iCCA as any adenocarcinoma involving the liver may be PET avid, rather the role of

FDG-PET is that of a staging modality. The role of FDG-PET in the management of iCCA, however, is controversial. Mass-forming iCCA tend to be more FDG avid than other morphological subtypes [119]. Some data have suggested that the potential benefit of FDG-PET resides largely in its ability to detect otherwise unsuspected metastasis [119,121,134,135]. In fact, FDG-PET was found to change the surgical management in up to 30% of patients [119,121,134]. Prior to surgical resection, PET scanning may be considered to help rule out an occult primary as well as to rule out otherwise occult metastatic disease.

Recommendations 4

Recommendations

- Pathological diagnosis is required for a definitive diagnosis of iCCA
Recommendation A1
- Pathological diagnosis of iCCA is based on the WHO classification for biliary tract cancer. Differentiation of metastatic adenocarcinoma from primary iCCA may require additional clinical and radiological and endoscopic evaluation
Recommendation B1
- Immunostaining to detect markers of hepatocellular carcinoma (e.g., GPC3, HSP70, and glutamine synthetase) or progenitor cell features (e.g., K19, EpCAM) is recommended to distinguish iCCA from mixed hepatocellular-cholangiocarcinoma tumors if this information will change management
Recommendation B1
- A presumed radiographic diagnosis is sufficient in non-cirrhotic patients in whom a decision has been made to proceed with surgical resection
Recommendation B1
- PET-scan is not accurate for early diagnosis of iCCA; its role as a staging modality remains controversial
Recommendation B2
- Serological tumor markers such as CA19-9 are insensitive for the diagnosis of iCCA and insufficient to establish the diagnosis, but may be of prognostic significance
Recommendation B1
- Assessment of resectability and/or intra- and extrahepatic metastatic disease, as well as venous and arterial invasion, is best accomplished using radiographic studies such as CT and/or MRI
Recommendation A1

Suggestions for future studies

- Future studies should focus on histopathologic features and markers to more specifically diagnose and stratify iCCA subtypes

Staging systems for iCCA

Traditionally, iCCA has been staged with HCC under the category of “primary liver cancers [136].” In fact, up until the current 7th edition of the American Joint Committee on Cancer/International Union Against Cancer (AJCC/UICC) staging manual, there was no distinct internationally recognized staging system for iCCA [137]. There are, however, important epidemiologic, etiologic, and biologic differences between iCCA and HCC [23,138]. As such, there has been an increasing realization of the importance of establishing a distinct staging system for iCCA [139].

Several staging systems have been proposed for iCCA, with two staging systems based on data from Japan [140,141]. One staging system of patients with mass-forming iCCA was based on multivariate modeling that included 14 clinical and 12 post-operative surgical and pathological factors. Several independent factors were associated with worse long-term survival including presence of vascular invasion, symptomatic disease, regional lymph node metastasis, and multiple tumors [141]. Based on these factors, the authors proposed the following staging schema: Stage 1 disease, solitary tumor without vascular invasion; Stage 2 disease, solitary tumor with vascular invasion; Stage 3a disease, multiple tumors with or without vascular invasion; Stage 3b disease, any tumor with regional lymph node metastasis; and Stage 4 disease, iCCA with distant metastasis [141]. Of note, tumor size was not included as a factor in the staging of patients with iCCA. A different proposed staging system for iCCA that included tumor size [140], which stratified patients based on tumor size of 2 cm or less vs. more than 2 cm, solitary vs. multiple tumors, and the presence or absence of hepatic vein, portal vein, or peritoneal invasion. Each of these factors was assigned a point and the staging was based on the additive summation of points. Distant metastasis and regional lymph node metastasis were also included in a binary fashion (e.g., absent vs. present) [140].

More recently, a large population-based Western cohort of patients with iCCA was reported, which evaluated the staging systems proposed by Japanese authors, as well as the 6th edition of the AJCC/UICC staging manual [142]. In this study, the authors noted that each of the previously proposed staging systems for iCCA performed poorly in their ability to predict long-term prognosis [142]. While previous studies had reported conflicting results regarding the impact of tumor size on prognosis [140,141], they found that tumor size had no effect on survival, either in overall or in multiple subgroup analyses [142]. The authors also noted that vascular invasion and multiple tumors had similar effects on prognosis, but the presence of both factors did not result in worse prognosis. The authors therefore proposed a simplified staging system based on the number of iCCA tumors, vascular invasion, and the presence of metastatic disease in the regional lymph node basin or at distant sites.

With the recent publication of the 7th edition of the AJCC/UICC staging manual, there is now a new distinct staging system for iCCA [137]. The 7th edition AJCC/UICC staging system largely reflects many of the proposals included in previous publications [137,142]. Specifically, tumor size is no longer a prognostic factor, rather, T-classification is based on the number of lesions, vascular invasion, intrahepatic metastasis, and invasion of adjacent structures [137]. Specifically, T1 tumors are solitary without vascular invasion; T2 disease includes multiple tumors (e.g., multi-focal disease, satellitosis, intrahepatic metastasis), as well as tumors associated with any type of vascular invasion (e.g., microvascular

or major vascular invasion); T3 tumors directly invade adjacent structures; and T4 disease includes tumors with any periductal-infiltrating component. As with most other solid liver, biliary, and gastrointestinal malignancies, AJCC/UICC staging also includes both an “N” and “M” sub-classification. Regional lymph node metastasis in the hilar, periduodenal, and peripancreatic nodes are considered N1 disease, while distant disease is considered M1 disease.

Although the 7th edition of the AJCC/UICC is still relatively new, the validity of the staging system has already been independently validated [143]. The authors of the validation study noted that patients were equally distributed among the AJCC/UICC 7th edition stages, which was not the case for the other staging systems examined. In addition, the 7th edition of the AJCC/UICC staging system for iCCA was more discriminating in predicting survival than the other staging systems evaluated, including the two Japanese classifications. There are, however, undoubtedly limitations to the current 7th edition the staging system for iCCA. For example, multiple tumors are classified as T2b. From a clinical standpoint, it is difficult to distinguish among patients with “multiple” tumors who have multi-focal disease vs. those with an index lesion and intrahepatic metastasis. In addition, the classification of T4 disease needs further validation in future studies that specifically examine the impact of this prognostic factor.

Taken together, while future refinements are likely, the current 7th edition AJCC/UICC staging schema should be the accepted and preferred staging system for resected iCCA.

Recommendations 5

Recommendations

- The 7th edition of the AJCC/UICC staging schema is currently the preferred staging system for resected iCCA

Recommendation B1

Suggestions for future studies

- Future studies should focus on stratifying nonsurgical patients for clinical studies using a clinical as opposed to a surgical staging process. Prognostic biomarkers should be explored in the setting of clinical investigations

Treatment

Surgical resection

Surgical resection is the mainstay for treatment of iCCA. As part of the pre-operative clinical work-up of the patient with possible iCCA, laboratory exams, including tumor markers such as carcinoembryonic antigen (CEA), CA 19-9, and alpha fetoprotein (AFP) should be obtained. Pre-operative cross-sectional imaging for iCCA should include either multi-detector, contrast-enhanced helical CT, or MRI/MRCP as discussed above. On cross-sectional imaging the distinct morphologic sub-types (i.e., mass-forming, periductal-infiltrating, and intraductal-growth) may have different characteristics

Guidelines

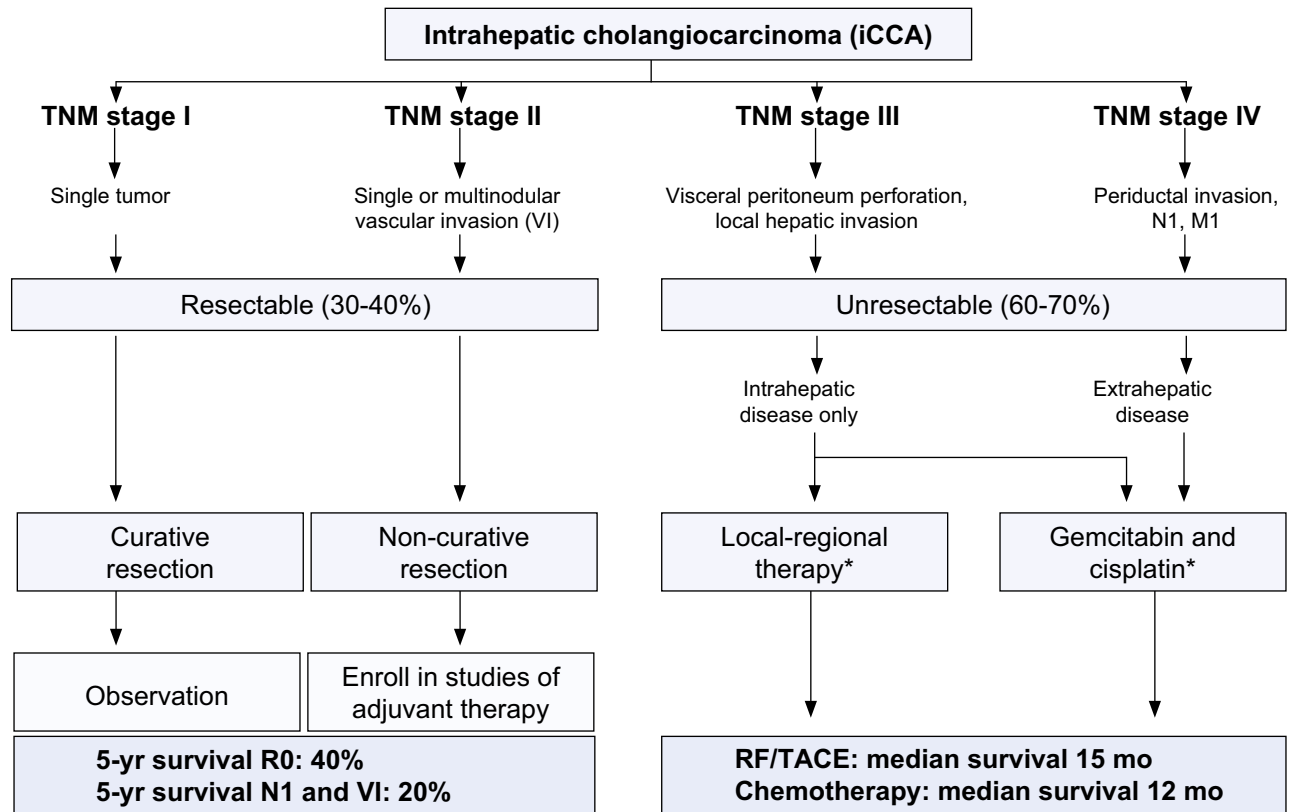


Fig. 3. A suggested treatment algorithm for patients with iCCA.* These are standard of practice recommendations. Larger and appropriate studies are required to provide evidence for standard of care guidelines.

[140]. For example, while periductal-infiltrating iCCA is often characterized by growth along the bile duct without mass formation, intra-ductal-growing iCCA may manifest as diffuse and marked duct ectasia with or without a grossly visible papillary mass or a focal stricture-like lesion with proximal ductal dilatation [140,144,145]. Overall, the mass-forming type of iCCA is the most common morphological subtype (>85% of cases). Liver function should be thoroughly assessed in patients with underlying liver cirrhosis, and restrictions for resection due to impaired liver function are recommended using criteria recommended for HCC [146].

Data on the role and yield of staging laparoscopy for iCCA are lacking. Because a subset of patients with biliary malignancies will have unsuspected metastatic disease, some surgeons have suggested that staging laparoscopy should be performed at the time of surgery. The data on the use of laparoscopy in the setting of resectable iCCA are, however, very limited. In a series of 22 patients with iCCA who underwent diagnostic laparoscopy, 6 patients (27%) who had previously undetected peritoneal or intrahepatic metastasis were identified with metastatic disease [147]. While such reports warrant future validation, currently there is insufficient evidence to recommend routine staging laparoscopy for patients undergoing surgery for iCCA.

Resection should be undertaken in those patients who are appropriate surgical candidates and who have potentially resectable disease (Fig. 3). Unfortunately, only about 20–40% of patients with potentially operable disease are offered surgical resection [148]. This may be due in part to the fact that patients with iCCA often present with large, locally advanced tumors in need of technically complex and challenging operations [149]. As with other

hepatic malignancies, the goal of surgical resection is to remove all the disease with negative microscopic (R0) margins while preserving an adequate remnant liver volume. Depending on the size and location of the iCCA lesion, this may require an extensive resection including adjacent structures such as the extrahepatic biliary tree. Extended hepatectomy and/or resection of the extrahepatic bile duct bifurcation has been considered necessary in 78% and 29% of iCCA cases, respectively, in order to obtain an R0 resection [150]. In another study among patients undergoing resection of iCCA, 49% of patients required an extended hepatectomy while 21% required a concomitant biliary resection and reconstruction [151]. In a separate report of one of the largest surgical series published to date that included several high volume centers, the authors noted that 73% of patients required either a hemi-hepatectomy or an extended hepatic resection [149]. Extensive resections and biliary reconstruction are, therefore, frequently necessary for patients with iCCA in order to obtain negative microscopic margins. While perioperative mortality rates are often reported to be less than 5% in these series [149,151], it is important to note that these outcomes reflect the results from highly specialized centers. As such, resection of iCCA is probably best performed at high-volume hepatobiliary centers and patients should be referred to these centers when resection is being considered [127,149,152–155].

While removal of clinically suspicious nodal disease is mandatory, the role of routine lymphadenectomy is less defined. In contrast to the practice of many Japanese centers, lymph node dissection is not routinely performed at the time of iCCA resection in most Western countries [156]. In fact, in a large population-based

Western series of patients undergoing resection approximately one-half of patients had at least one lymph node examined [142]. Of note, however, was the finding that among patients who did have lymph nodes examined, metastatic nodal disease was found in up to 30% of patients [142]. Despite this, some investigators have argued that routine lymphadenectomy is unnecessary. For example, in a report on 68 patients with mass-forming iCCA, 36 of who underwent concomitant lymphadenectomy [155], the authors reported that among those patients without lymph node involvement, there was no difference in survival or pattern of recurrence according to the use of lymph node dissection. The authors concluded that routine lymphadenectomy was not necessary in patients with mass-forming iCCA when lymph node involvement is not clinically apparent. Other investigators have noted that N1 status adversely affects overall survival and also influences the relative effect of tumor number and vascular invasion on prognosis [149]. Specifically, in a study encompassing 248 patients with iCCA who underwent lymphadenectomy, 74 (30%) had lymph node metastasis [149]. Lymph node metastasis was associated with worse median survival; in addition, although patients with no lymph node metastasis could be stratified by tumor number and vascular invasion, among patients with N1 disease, multiple tumors and vascular invasion, either alone or together, failed to discriminate patients into discrete prognostic groups. In turn, these investigators advocated that routine lymphadenectomy should be strongly considered for iCCA as up to 30% of patients will have nodal metastasis and this information has important prognostic implications. Other investigators, including the AFC-iCCA-2009 study group, have similarly recommended that routine lymphadenectomy should be performed at the time of iCCA resection, as lymph node metastasis is more prevalent in iCCA than in other tumors that liver surgeons may be used to dealing with [143]. There is already an established role for lymph node clearance for other sub-types of hepatobiliary malignancies (e.g., fibrolamellar HCC, gallbladder cancer). Given the established strong prognostic role of lymph node metastasis for iCCA, lymphadenectomy should be strongly considered at the time of surgery.

Outcomes following surgical resection of iCCA remain relatively guarded. Recurrence has been reported to occur in up to 50–60% of patients with a median-disease free survival of 26 months [151,157,158]. Factors associated with an increase in recurrence include those factors that form the basis of staging for iCCA: multiple tumors, vascular invasion, and lymph node metastasis. While the liver is the most common site of recurrence (e.g., 50–60%), recurrence in regional lymph nodes or the peritoneum is not uncommon (e.g., 20–25%) [157,158]. A small subset of patients with liver only recurrence may be candidates for either ablation or re-resection [151,157,158]. Five-year survival and overall survival after surgical resection of iCCA ranges from 15% to 40% in most series [127,155,159–161].

There are several factors that are particularly associated with patient survival, and in turn, need to be considered when selecting

patients for operative therapy. Several studies have reported that the presence of metastatic nodal disease is one of the most powerful, independent determinants of survival [149,162]. Specifically, patients undergoing surgical resection who are found to have lymph node metastasis have a 5-year survival of less than 20%. It is important to note that most data on the prognostic implications of lymph node metastasis are derived from surgical studies, and therefore largely include patients with microscopic lymph node disease. There is minimal data on the prognosis of patients with iCCA and clinically positive hilar lymph node disease that is identified preoperatively. However, extrapolating from colorectal data, [163] the prognosis of patients with “gross” hilar adenopathy is particularly poor with few long-term survivors. In addition to lymph node disease, the presence of either intrahepatic metastasis or major vascular invasion similarly have a 5-year survival in the range of 20% or less with the vast majority of patients experiencing a recurrence [149,164]. Given the very poor prognosis of patients who have clinically evident lymph node metastasis, intrahepatic metastasis or major vascular invasion, these factors should be considered relatively strong contraindications to surgical resection. While surgery may be warranted in a select subset of patients with these clinical characteristics, decisions about therapy should be made in a multidisciplinary setting. Strong consideration should be given to treating these patients with some type of systemic or loco-regional therapy to allow for a better evaluation of the biology of the disease prior to any surgical consideration.

For those patients undergoing resection – especially those with N1 disease – adjuvant therapy should be strongly considered. There have been two randomized studies examining the benefit of adjuvant therapy following resection. A phase 3 randomized controlled trial evaluated the benefit of post-operative adjuvant chemotherapy compared with surgery alone in patients with resected pancreato-biliary carcinoma [165]. The primary endpoint was survival and patients were randomized to receive intravenous mitomycin C and 5-FU followed by 5-FU orally until disease recurrence or surveillance. There appeared to be an improved disease free survival (20.3% in the treatment group compared with 11.6% for surveillance) for gallbladder carcinoma (n = 140), but no benefit was found for pancreas adenocarcinoma, CCA (n = 139), or ampullary cancers; overall, the study was underpowered to prove a treatment benefit. This is in contrast to the known benefit of adjuvant treatment in pancreas cancer [166]. A similar randomized trial was conducted recruiting a population of CCA, small bowel, ampullary and peri-ampullary cancers to receive 5-FU or Gemcitabine [167]. The 96 patients in the CCA group did not appear to benefit from adjuvant chemotherapy with either drug but these data are clearly underpowered to support any significant outcome. Table 3 gives a list of current adjuvant studies that involved randomization of patients to either a specific treatment vs. surveillance, in an attempt to address formally the issue of adjuvant systemic therapy in biliary tract cancer.

Table 3. Trials of adjuvant therapy in BTC.

Study title	CI, Location	Chemotherapy	Numbers planned	Primary end point	Completion of accrual
BILCAP	Primrose, UK	Capecitabine	360	2 year disease free	Q1 2013
PRODIGE-12	Boucher, France	Oxaliplatin-gemcitabine	360	Disease free survival	Q1 2012
ACTICCAA-1	Arnold, Germany	Cisplatin-gemcitabine	280	Disease free survival	Q1 2015

Guidelines

Recommendations 6

Recommendations

- Surgical resection is the treatment of choice for iCCA
Recommendation B1
- Patients with iCCA with single intrahepatic nodules and no evidence of disease deseminatation are optimal candidates for resection. Patients demonstrating intrahepatic metastases, vascular invasion or obvious lymph node metastases should not undergo resection
Recommendation B1
- Staging laparoscopy cannot be universally endorsed in the staging of iCCA
Recommendation C2
- Lymphadenectomy of regional nodes is recommended given its prognostic value
Recommendation B2
- In cirrhotic patients, advanced liver failure precludes surgical resection
Recommendation A1
- There is no established adjuvant therapy after resection
Recommendation B1

Suggestions for future studies

- Future studies should focus on stratifying patients for surgery based on intent to treat, overall survival, and incorporating cost-effectiveness analysis

Liver transplantation for iCCA and mixed HCC-iCCA

Liver transplantation (LT) for iCCA is highly controversial. Although LT for pCCA is well defined in regards to selection criteria, the need for neoadjuvant therapy and long term outcomes [168], this is not the case for iCCA. The published data regarding LT for iCCA employs non-uniform selection criteria, is limited in number of patients undergoing LT, has disparate neoadjuvant and adjuvant treatment protocols, and highly variable outcomes. Herein, we will review in more detail those studies published after the year 2000. An early study reported a 39% three-year actuarial survival on 16 patients undergoing LT for iCCA with variable and selective adjuvant chemotherapy [169]. Univariate analysis performed by combining pCCA with the iCCA patients suggested tumor size, invasion of adjacent organs, and multiple nodules were poor prognostic variables; there was an insufficient number of patients for a formal multivariate analysis. Another study reported on LT in 11 patients with iCCA who received neither adjuvant nor neoadjuvant therapy [170]. Three-year overall survival was 50% with long-term survival achieved only in those patients with Stage 1 or 2 disease (absence of lymph node metastases or vascular involvement). The collective Spanish experience was published on 23 patients with iCCA undergoing LT again in whom 7 received unspecified adjuvant anti-cancer therapy [171]. The three-year overall survival was 65% and perineural invasion was the only significant adverse prognostic factor in their patient population. Another study reported on 10 patients following LT for iCCA with a three-year overall survival

of 50% without specified anti-cancer therapy [172]. The UCLA group first reported on 25 patients undergoing LT for iCCA in whom 9 underwent adjuvant or neoadjuvant therapy [173]. The adverse prognostic factors were perineural invasion and multifocality whereas neoadjuvant plus adjuvant anti-cancer therapy was associated with improved long-term survival. Overall survival for the iCCA was not reported. In a subsequent paper by this group, the outcome data were modeled to obtain a predictive index [174]. Unfortunately, this analysis grouped iCCA along with pCCA. Seven predictive features were identified including multifocality, perineural invasion, infiltrative pattern of tumor growth, lack of adjuvant or neoadjuvant anti-cancer therapy, lymphovascular invasion, and history of PSC. Patients without adverse prognostic factors who received anti-cancer therapy had excellent long-term survival; however, given that iCCA and pCCA were grouped together it is difficult to dissect how the prognostic index applies to iCCA. More recently their current protocol has been reviewed which stratifies patients according to risk of recurrence, employs neoadjuvant therapy, and advocates assessing the response to neoadjuvant therapy in high-risk patients before proceeding on to LT [175]. In summary, LT for iCCA is not a futile procedure, but the overall outcomes are suboptimal compared to the 74% five-year survival for patients with cirrhosis undergoing LT [176].

As noted above, cirrhosis and viral Hepatitis C and B are risk factors for iCCA [6], and therefore, the same risk factors which are well-established for HCC may also predispose the patient to iCCA. Indeed, certain cancers contain features of both cancers; these malignancies are referred to as mixed HCC-iCCA. In mixed tumors, the presence of cholangiocarcinoma elements can be confirmed by a positive cytokeratin 19 (CK19) and cytokeratin 7 (CK7) staining by immunohistochemistry. With the recognition that patients can harbor mixed HCC-iCCA tumors [177,178], a liver biopsy should be considered for atypical lesions (lesions not diagnostic for HCC by classical imaging criteria on cross-sectional studies) prior to LT. Mixed HCC-iCCA lesions have worse outcomes following LT than patients with HCC [177,178] with a five-year recurrence rate of 65% [178]. Such patients should either not undergo transplantation or be enrolled in research protocols combining adjuvant or neoadjuvant therapy for iCCA in the transplant setting.

Recommendations 7

Recommendations

- LT is not recommended for iCCA or mixed HCC-iCCA because results are well below those published for standard indications; however, this recommendation is based on limited data. LT should only be offered in centers with designed clinical research protocols employing adjuvant or neoadjuvant therapy
Recommendation B2
- Protocols examining the efficacy of LT for iCCA should be limited to lesions without lymphovascular invasion
Recommendation B2

Suggestions for future studies

- Future studies should focus on standardized selection criteria plus adjuvant and/or neoadjuvant therapy with LT as definite therapy for iCCA

Loco-regional therapy in the management of iCCA

Although major hepatectomy is a potentially curative treatment for iCCA, many patients present with intrahepatic disease beyond the criteria for resection. For example, resectability rates are generally quite low and vary among series from 18% to 70% [31,179]. In addition, many patients do not qualify for resection because of comorbidities; these patients may be eligible for loco-regional therapy, as well as best supportive care. Since the current tumor-node-metastasis (TNM) staging system for iCCA is based on surgical acquisition of tissue, this staging system may be inadequate for evaluating outcomes of loco-regional therapies. An ideal classification system for iCCA should therefore not require surgical resection.

Few studies to date have evaluated the evidence-based efficacy of loco-regional treatments in patients with unresectable iCCA. Loco-regional therapy in these patients may provide symptomatic relief, and might have a positive effect on survival [180]. Loco-regional therapies for patients with unresectable iCCA include radiation therapy (RT), transarterial chemoembolization (TACE), transarterial chemoinfusion (TACI), radioembolization and radiofrequency ablation (RFA). The website www.ClinicalTrials.gov lists more than 10 clinical trials of loco-regional therapies for unresectable iCCA that are currently ongoing or recruiting, and the outcomes of these trials are awaited.

Radiation therapy

Radiation therapy consists of (i) external-beam RT (EBRT), including three dimensional-conformal RT (3D-CRT), intensity-modulated RT (IMRT) and stereotactic body radiotherapy (SBRT), (ii) brachytherapy, and (iii) proton therapy. The role of EBRT in patients with unresectable iCCA is not clear. Most studies of RT have been performed on patients with biliary tract cancer, with few performed on patients with iCCA. To date, no prospective randomized studies have shown that EBRT benefits these patients, although several single institution retrospective studies have suggested that EBRT has palliative advantages, including a reduction in tumor burden and an anecdotal positive effect on survival [181–183]. One-year survival rates of iCCA patients treated with EBRT have been found to range from 36.1% to 73% [181–184]. Although tumor control was not generally defined, its rate varied from 36% to 100%, and grade 3–4 toxicities were infrequent in these studies. EBRT may completely or partially relieve pain and obstructive jaundice in patients with unresectable iCCA [181,182].

Although there is no clear evidence for EBRT in the treatment of iCCA patients, methods such as SBRT may be considered in multidisciplinary and adjuvant approaches in the future. A recent retrospective analysis of 3839 patients with iCCA from the Surveillance, Epidemiology, and End Results (SEER) database showed that adjuvant and definitive radiation treatment prolonged survival, although cure rates remained low [185]. The median overall survival in patients treated with surgery and adjuvant RT, surgery alone, RT alone, and supportive care alone was 11, 6, 7, and 3 months, respectively. Other retrospective studies also suggest that adjuvant RT following resection had a survival benefit in iCCA patients with regional lymph node metastasis [186] and that concurrent EBRT with systemic chemotherapy prolonged progression-free survival [187]. Moreover, SBRT following chemotherapy was well tolerated and early local control was promising [188]. There are no data on the use of brachytherapy and proton therapy for evaluating the outcomes in patients with iCCA.

Transarterial chemoembolization (TACE), transarterial chemoinfusion (TACI), and transarterial radioembolization (TARE)

TACE is the main treatment modality for patients with intermediate stage HCC not amenable to surgical therapies or local ablation. The rationale for TACE is that the intra-arterial infusion of a cytotoxic agent followed by embolization of the tumor-feeding blood vessels will result in strong cytotoxic and ischemic effects [189]. Currently, there are two types of TACE procedure, conventional TACE (cTACE) and drug-eluting bead TACE (debTACE). Because HCCs are usually hypervascular, TACE may have anti-tumor effects. Although iCCAs are not overtly hypervascular on CT or MRI studies, tumor blushes on angiography are frequently identified in patients with iCCA [135]. Nonetheless, there have been limited studies of TACE in iCCA patients and there is an absence of trials systematically evaluating outcomes with TACE in this population [190]. A single-center, retrospective cohort study of 155 patients with iCCA reported a median overall survival that was significantly longer in the patients treated with cTACE group (12.2 months) than in the non-TACE treated cohort (3.3 months), and that the tumor control rate in the former group was 89%, including partial responses in 23% and stable disease in 66% [191]. A recent meta-analysis of 14 trials of transarterial therapies in patients with unresectable cholangiocarcinoma found that the calculated weighted cumulative median overall survival from date of diagnosis was 15.6 ± 1.1 months; 49.8% of all patients had stable disease by Response Criteria in Solid Tumors (RECIST) criteria [192]. The survival outcomes of cTACE may be improved by sequential systemic chemotherapy [193,194]. A retrospective analysis found that adjuvant cTACE after curative surgery did not delay recurrence but may prolong the overall survival of patients with early recurrence [195].

debTACE was developed to improve the anti-tumor activity and clinical benefits of chemoembolization. The efficacy of debTACE in patients with iCCA is unclear [196], although a retrospective comparative study reported an increase in median survival using combination debTACE and systemic chemotherapy (30 months) compared to those patients treated with systemic chemotherapy alone (12.7 months) [197]. A recent study found that irinotecan-debTACE prolonged survival relative to cTACE (11.7 vs. 5.7 months) [198].

Transarterial chemoinfusion (TACI) describes transcatheter intra-arterial chemotherapy without embolization, which differentiates it from TACE and systemic chemotherapy. The efficacy of TACI is unclear but retrospective studies reported the favorable survival outcomes in a small number of patients with unresectable iCCA [199–201].

Transarterial radioembolization (TARE) is defined as the infusion of radioactive substances, such as iodine-131 (^{131}I)-labeled lipiodol or microspheres containing yttrium-90 (^{90}Y) or similar agents, into the hepatic artery [189]. These transarterially-injected radioactive substances are delivered to hypervascular tumor-bearing areas, where they emit low-penetration, high-energy radiation (β -particles) to tumors. To date, no randomized controlled trials have compared the efficacy of radioembolization with cTACE or systemic treatment in patients with unresectable HCC or iCCA. Several clinical trials of radioembolization in patients with unresectable iCCA are ongoing, and outcomes are awaited. Retrospective studies have reported that the disease control rates of radioembolization in patients with iCCA range from 72% to 95% and that median overall survival ranges from 9.3 to 22 months [202–204]. Prognostic factors for outcomes included Eastern

Guidelines

Cooperative Oncology Group (ECOG) performance status, tumor burden, tumor type, portal vein invasion, and tumor response. Radioembolization was found to be relatively safe, with the most frequent adverse events being fatigue, abdominal pain, and increases of serum bilirubin.

Ablation

All guidelines recommend radiofrequency ablation (RFA) as a standard treatment for patients with small, early stage HCC not suitable for surgical therapies [146]. There have been few studies of RFA in patients with iCCA and the outcomes have been less optimal than those observed with HCC. RFA may provide local control of small, localized, unresectable lesions with no evidence of extrahepatic spread [114,115,205–210]. Rates of primary technical effectiveness and early necrosis of small (\leq roughly 3.0 cm) tumors were reported to be 90–100%. Median overall survival ranged from 33 to 38.5 months, one-year survival rates from 84.6% to 100%, and three-year survival rates from 43.3% to 83.3%. These findings suggest that RFA may have survival benefits when compared with other palliative treatment methods in patients with small, single iCCA lesions. In patients with local recurrence or residual tumor after surgery with curative intent, RFA resulted in a median overall survival of 27.4 to 51 months [114,115,207,211]. Although RFA has been the most studied, other alternative approaches such as microwave ablation are also feasible [212].

Recommendations 8

Recommendations

- There are no established first-line local-regional therapeutic options for patients with non-resectable iCCA
Recommendation B1
- EBRT cannot be recommended as standard therapy for patients with unresectable iCCA. Additional clinical trials of single, combination or adjuvant therapy are needed to establish its role in this population
Recommendation B2
- TACE and TARE have shown anti-tumor effects with acceptable toxicities in patients with iCCA but require further examination in appropriately designed clinical trials and therefore cannot be recommended as standard therapy for patients with unresectable iCCA
Recommendation B2
- TACI is not recommended for management of patients with unresectable iCCA
Recommendation C2
- Ablation approaches may be considered for small, single lesions <3 cm if surgery is not an option, but additional clinical trials are needed to establish its role in this population
Recommendation C2

Suggestions for future studies

- Randomized controlled trials are recommended to establish first-line local-regional treatment options for patients with unresectable iCCA

Systemic therapy

Trials with systemic therapy for CCA have been fraught with disease heterogeneity, grouping all patients with biliary tract cancers into a single disease category. Likewise, as compared to breast cancer, lung cancer, and even pancreatic cancer the trials are limited in regards to patient numbers. Thus, any extrapolation of clinical trial information regarding biliary tract cancer solely to iCCA is compromised. Therefore, positive data may be considered a current practice standard from a pragmatic perspective, but are far too limited to be a “standard of care.”

Systemic therapies

The outcome for patients with advanced and inoperable biliary tract cancer with treatment compared to best supportive care has been investigated in two randomized studies [213,214]. Although underpowered, both suggested a benefit for chemotherapy with median survivals for those receiving no chemotherapy of 2.5–6 months. A comprehensive analysis of 112 clinical trials in advanced biliary tract malignancies have been published mostly including single arm phase 2 studies [215]. They suggested that Gemcitabine and fluoropyrimidine based regimens were active but also that the addition of Cisplatin appeared to add benefit. This is consistent with the published randomized data (Table 4). These studies in themselves are not sufficiently robust to define a standard regimen, primarily because of statistical poverty and some of the difficulty in interpretation is highlighted by a dramatic difference between the response rates (9–57%) yet a relatively small effect on survival.

The UK ABC studies

Based on the potential efficacy of Gemcitabine and Cisplatin derived from the unrandomized phase 2 data, the UK NCRN ABC-01 study compared Cisplatin and Gemcitabine (Cisplatin 25 mg/m² followed by Gemcitabine 1000 mg/m², each on days 1 and 8 of a 21-day cycle, CisGem) with Gemcitabine (Gemcitabine 1000 mg/m² on days 1, 8, and 15 of a 28-day cycle) with 6-month progressive free survival (PFS) as the primary endpoint [216]. It demonstrated improved 6-month PFS in favor of CisGem compared to Gemcitabine alone (57.1 vs. 45.5%). Consequently, the study was expanded into a phase 3 study with an identical protocol except for the primary endpoint which became overall survival and the addition of quality of life analysis, the UK advanced biliary cancer 02 (ABC02) study. An additional 324 patients were recruited allowing a pre-planned combined analysis of 410 patients. Median overall survival was 11.7 months for patients receiving CisGem compared to 8.1 months in patients receiving Gem alone [217]. Subgroup analysis only including 80 patients with iCCA showed a benefit favoring the combination arm. Patients receiving CisGem benefited significantly and this regimen has become an international practice standard as well as the backbone for subsequent studies [217]. These data are supported by a randomized phase 2 study of 83 patients using the same protocol [218]. The median overall survival was 11.2 vs. 7.7 months, consistent with the ABC02 data. The ABC02 study has demonstrated that treatment defining studies can be

Table 4. Randomized trials in advanced BTC before ABC02.

First author	Number of patients	Year of publication	Survival	Chemotherapy	[Ref.]
Glimelius	37	1998	6 vs. 2.5 mo	5FU/etoposide vs. BSC	[231]
Takada	31	1998	6 vs. 3 mo	5FU/doxorubicin/mitomycin-C vs. BSC	[165]
Sharma	87	2010	4.5, 4.6 vs. 9.5 mo	BSC, 5FU and oxaliplatin/gemcitabine	[214]
Kornek	51	2004	6.7 vs. 9.3 mo	Mitomycin-C/gemcitabine vs. mitomycin-C/capecitabine	[232]
Ducreux	58	2005	5 vs. 8 mo	5FU vs. cisplatin/5FU	[233]
Rao	50	2005	12 vs. 9 mo	5FU/etoposide vs. epirubicin, cisplatin and 5FU	[234]

BSC, best supportive care.

successfully performed in biliary tract cancers and has stimulated the international community to improve outcomes.

Second line therapies

There are 5 reported studies of second line therapy for biliary tract cancer. The most robust is a phase 2 study of Gemcitabine in 32 patients refractory to 5-FU based chemotherapy which reported a response rate of 7%, stable disease in 21%; a median time to progression (TTP) of 1.6 months and median survival of 4.1 months. Lower albumin levels (<3.5 g/dl) predicted shorter survival [219]. A phase 2 study of 5-FU, doxorubicin and mitomycin-C (FAM) in 31 patients with pancreas (n = 15) and biliary tract (n = 16) cancers after Gemcitabine-based chemotherapy reported a response rate of 13%, stable disease 26%, median TTP 2.3 months, and survival of 6.7 months [52]. The three remaining studies are case reports of 6, 4, and 2 patients respectively from which no conclusions can be drawn. There is therefore no significant evidence that further chemotherapy beyond progression of first-line chemotherapy improves survival.

Biological therapies in biliary tract malignancy

The efficacy of biological therapies in biliary tract cancers has been mixed. Twenty eight patients were treated with Selumetinib, a MEK1/2 inhibitor [220]. Toxicity was manageable and the disease control rate was 68% with an overall survival of 9.8 months. A different study randomized 150 patients between a Gemcitabine-Oxaliplatin chemotherapy backbone with or without the anti-EGFR antibody Cetuximab [221]. The PFS was 5.3 vs. 6 months and overall survival 12 vs. 11 months for the chemotherapy and combination arms respectively and no phase 3 study is planned. Whether this reflects a specific biliary tract effect or resembles that which has been found for Oxaliplatin and Cetuximab combinations in bowel and esophageal cancer is uncertain. A third study randomized 103 patients between a Gemcitabine chemotherapy backbone with or without Sorafenib [222]. Disease control and overall survival were not improved in the Sorafenib group and was associated with significantly more toxicity. Translational analysis to define responsive subgroups is critical to ensure that benefiting subgroups can be identified.

Recommendations 9

Recommendations

- Cisplatin and Gemcitabine is a systemic therapy practice standard for iCCA in patients with ECOG performance status 0 or 1, but the data are too limited to make this an established standard of care
Recommendation B2
- There is no significant evidence that further chemotherapy beyond progression of first-line chemotherapy improves survival
Recommendation B2

Suggestions for future studies

- Randomized controlled trials selecting patients with iCCA are urgently needed. Randomized controlled trials in which patients with iCCA have sufficient statistical power to determine the standard of care are needed
- Further studies should focus on standardized selection criteria and comparator arms evaluating systemic therapy in homogenous groups of patients with iCCA
- The use of novel molecular strategies to define homogenous cohorts within the iCCA population is needed

Conflict of interest

The authors declared that they do not have anything to disclose regarding funding or conflict of interest with respect to this manuscript.

Acknowledgements

This practice guideline was produced in collaboration with the Practice Guidelines Committee of the International Liver Cancer Association (ILCA). This committee provided extensive peer review of the manuscript. Members of the Practice Guidelines Committee include Pierre Bedossa, Ann Lii Cheng, Pierre-Alain Clavien, Massimo Colombo, Korosh Khalili, Lewis Roberts, Myron

Guidelines

Schwartz, Andrew Zhu, and chairman Morris Sherman. John Bridgewater is partly supported by the UCLH/UCL comprehensive biomedical centre. SK is grateful to the NIHR Biomedical Research Centre Funding scheme at Imperial College of Medicine for infrastructure support. The outstanding secretarial service of Courtney Hoover in assembling this document is gratefully acknowledged.

References

- [1] Fan B, Malato Y, Calvisi DF, Naqvi S, Razumilava N, Ribback S, et al. Cholangiocarcinomas can originate from hepatocytes in mice. *J Clin Invest* 2012;122:2911–2915.
- [2] Sekiya S, Suzuki A. Intrahepatic cholangiocarcinoma can arise from Notch-mediated conversion of hepatocytes. *J Clin Invest* 2012;122:3914–3918.
- [3] Wistuba II, Gazdar AF. Gallbladder cancer: lessons from a rare tumour. *Nat Rev Cancer* 2004;4:695–706.
- [4] Blehacz B, Komuta M, Roskams T, Gores GJ. Clinical diagnosis and staging of cholangiocarcinoma. *Nat Rev Gastroenterol Hepatol* 2011;8:512–522.
- [5] Yang JD, Kim B, Sanderson SO, Sauver JS, Yawn BP, Larson JJ, et al. Biliary tract cancers in Olmsted County, Minnesota, 1976–2008. *Am J Gastroenterol* 2012;107:1256–1262.
- [6] Razumilava N, Gores GJ. Classification, diagnosis, and management of cholangiocarcinoma. *Clin Gastroenterol Hepatol* 2013;11:13–21. [e11; quiz e13–e14].
- [7] Guyatt GH, Oxman AD, Kunz R, Falck-Ytter Y, Vist GE, Liberati A, et al. Going from evidence to recommendations. *BMJ* 2008;336:1049–1051.
- [8] Bragazzi MC, Carpino G, Venere R, Semeraro R, Gentile R, et al. Cholangiocarcinoma: epidemiology and risk factors. *Translational Gastrointestinal Cancer* 2012;1:21–32.
- [9] Khan SA, Toledano MB, Taylor-Robinson SD. Epidemiology, risk factors, and pathogenesis of cholangiocarcinoma. *HPB (Oxford)* 2008;10:77–82.
- [10] Shaib Y, El-Serag HB. The epidemiology of cholangiocarcinoma. *Semin Liver Dis* 2004;24:115–125.
- [11] Shaib YH, Davila JA, McGlynn K, El-Serag HB. Rising incidence of intrahepatic cholangiocarcinoma in the United States: a true increase? *J Hepatol* 2004;40:472–477.
- [12] Taylor-Robinson SD, Toledano MB, Arora S, Keegan TJ, Hargreaves S, Beck A, et al. Increase in mortality rates from intrahepatic cholangiocarcinoma in England and Wales 1968–1998. *Gut* 2001;48:816–820.
- [13] Patel T. Increasing incidence and mortality of primary intrahepatic cholangiocarcinoma in the United States. *Hepatology* 2001;33:1353–1357.
- [14] West J, Wood H, Logan RF, Quinn M, Aithal GP. Trends in the incidence of primary liver and biliary tract cancers in England and Wales 1971–2001. *Br J Cancer* 2006;94:1751–1758.
- [15] Alvaro D, Crocetti E, Ferretti S, Bragazzi MC, Capocaccia R. Descriptive epidemiology of cholangiocarcinoma in Italy. *Dig Liver Dis* 2010;42:490–495.
- [16] von Hahn T, Ciesek S, Wegener G, Plentz RR, Weismuller TJ, Wedemeyer H, et al. Epidemiological trends in incidence and mortality of hepatobiliary cancers in Germany. *Scand J Gastroenterol* 2011;46:1092–1098.
- [17] Shin HR, Oh JK, Lim MK, Shin A, Kong HJ, Jung KW, et al. Descriptive epidemiology of cholangiocarcinoma and clonorchiasis in Korea. *J Korean Med Sci* 2010;25:1011–1016.
- [18] Khan SA, Taylor-Robinson SD, Toledano MB, Beck A, Elliott P, Thomas HC. Changing international trends in mortality rates for liver, biliary and pancreatic tumours. *J Hepatol* 2002;37:806–813.
- [19] Patel T. Worldwide trends in mortality from biliary tract malignancies. *BMC Cancer* 2002;2:10.
- [20] Jepsen P, Vilstrup H, Tarone RE, Friis S, Sorensen HT. Incidence rates of intra- and extrahepatic cholangiocarcinomas in Denmark from 1978 through 2002. *J Natl Cancer Inst* 2007;99:895–897.
- [21] Tyson GL, El-Serag HB. Risk factors for cholangiocarcinoma. *Hepatology* 2011;54:173–184.
- [22] McLean L, Patel T. Racial and ethnic variations in the epidemiology of intrahepatic cholangiocarcinoma in the United States. *Liver Int* 2006;26:1047–1053.
- [23] McGlynn KA, Tarone RE, El-Serag HB. A comparison of trends in the incidence of hepatocellular carcinoma and intrahepatic cholangiocarcinoma in the United States. *Cancer Epidemiol Biomarkers Prev* 2006;15:1198–1203.
- [24] Khan SA, Emadossady S, Ladeb NG, Thomas HC, Elliott P, Taylor-Robinson SD, et al. Rising trends in cholangiocarcinoma: is the ICD classification system misleading us? *J Hepatol* 2012;56:848–854.
- [25] de Martel C, Plummer M, Franceschi S. Cholangiocarcinoma: descriptive epidemiology and risk factors. *Gastroenterol Clin Biol* 2010;34:173–180.
- [26] International classification of diseases for oncology (ICD-O). In: Organisation GSWH; 2000.
- [27] Malhi H, Gores GJ. Cholangiocarcinoma: modern advances in understanding a deadly old disease. *J Hepatol* 2006;45:856–867.
- [28] Deoliveira ML, Schulick RD, Nimura Y, Rosen C, Gores G, Neuhaus P, et al. New staging system and a registry for perihilar cholangiocarcinoma. *Hepatology* 2011;53:1363–1371.
- [29] Welzel TM, McGlynn KA, Hsing AW, O'Brien TR, Pfeiffer RM. Impact of classification of hilar cholangiocarcinomas (Klatskin tumors) on the incidence of intra- and extrahepatic cholangiocarcinoma in the United States. *J Natl Cancer Inst* 2006;98:873–875.
- [30] Shin HR, Oh JK, Masuyer E, Curado MP, Bouvard V, Fang Y, et al. Comparison of incidence of intrahepatic and extrahepatic cholangiocarcinoma—focus on East and South-Eastern Asia. *Asian Pac J Cancer Prev* 2010;11:1159–1166.
- [31] Nakeeb A, Pitt HA, Sohn TA, Coleman J, Abrams RA, Piantadosi S, et al. Cholangiocarcinoma. A spectrum of intrahepatic, perihilar, and distal tumors. *Ann Surg* 1996;224:463–473. [discussion 473–465].
- [32] DeOliveira ML, Cunningham SC, Cameron JL, Kamangar F, Winter JM, Lillemoed KD, et al. Cholangiocarcinoma: thirty-one-year experience with 564 patients at a single institution. *Ann Surg* 2007;245:755–762.
- [33] Khan SA, Thomas HC, Davidson BR, Taylor-Robinson SD. Cholangiocarcinoma. *Lancet* 2005;366:1303–1314.
- [34] Palmer WC, Patel T. Are common factors involved in the pathogenesis of primary liver cancers? A meta-analysis of risk factors for intrahepatic cholangiocarcinoma. *J Hepatol* 2012;57:69–76.
- [35] Kaewpitoon N, Kaewpitoon SJ, Pengsaa P, Sripa B. *Opisthorchis viverrini*: the carcinogenic human liver fluke. *World J Gastroenterol* 2008;14:666–674.
- [36] Shin HR, Lee CU, Park HJ, Seol SY, Chung JM, Choi HC, et al. Hepatitis B and C virus, *Clonorchis sinensis* for the risk of liver cancer: a case-control study in Pusan, Korea. *Int J Epidemiol* 1996;25:933–940.
- [37] Honjo S, Srivatanakul P, Sriplung H, Kikukawa H, Hanai S, Uchida K, et al. Genetic and environmental determinants of risk for cholangiocarcinoma via *Opisthorchis viverrini* in a densely infested area in Nakhon Phanom, northeast Thailand. *Int J Cancer* 2005;117:854–860.
- [38] Sawanyawisuth K. Genes and cholangiocarcinoma. *Southeast Asian J Trop Med Public Health* 2009;40:701–712.
- [39] Soreide K, Korner H, Havnen J, Soreide JA. Bile duct cysts in adults. *Br J Surg* 2004;91:1538–1548.
- [40] Blehacz BR, Gores GJ. Cholangiocarcinoma. *Clin Liver Dis* 2008;12:131–150. [ix].
- [41] Mabrut JY, Bozio G, Hubert C, Gigot JF. Management of congenital bile duct cysts. *Dig Surg* 2010;27:12–18.
- [42] Edil BH, Cameron JL, Reddy S, Lum Y, Lipsett PA, Nathan H, et al. Choledochal cyst disease in children and adults: a 30-year single-institution experience. *J Am Coll Surg* 2008;206:1000–1005. [discussion 1005–1008].
- [43] Lee TY, Lee SS, Jung SW, Jeon SH, Yun SC, Oh HC, et al. Hepatitis B virus infection and intrahepatic cholangiocarcinoma in Korea: a case-control study. *Am J Gastroenterol* 2008;103:1716–1720.
- [44] Welzel TM, Mellemkjaer L, Gloria G, Sakoda LC, Hsing AW, El Ghormli L, et al. Risk factors for intrahepatic cholangiocarcinoma in a low-risk population: a nationwide case-control study. *Int J Cancer* 2007;120:638–641.
- [45] Zhou YM, Yin ZF, Yang JM, Li B, Shao WY, Xu F, et al. Risk factors for intrahepatic cholangiocarcinoma: a case-control study in China. *World J Gastroenterol* 2008;14:632–635.
- [46] Donato F, Gelatti U, Tagger A, Favret M, Ribero ML, Callea F, et al. Intrahepatic cholangiocarcinoma and hepatitis C and B virus infection, alcohol intake, and hepatolithiasis: a case-control study in Italy. *Cancer Causes Control* 2001;12:959–964.
- [47] Liu ZY, Zhou YM, Shi LH, Yin ZF. Risk factors of intrahepatic cholangiocarcinoma in patients with hepatolithiasis: a case-control study. *Hepatobiliary Pancreat Dis Int* 2011;10:626–631.
- [48] Shaib YH, El-Serag HB, Davila JA, Morgan R, McGlynn KA. Risk factors of intrahepatic cholangiocarcinoma in the United States: a case-control study. *Gastroenterology* 2005;128:620–626.

- [49] Sorensen HT, Friis S, Olsen JH, Thulstrup AM, Møller M, Linet M, et al. Risk of liver and other types of cancer in patients with cirrhosis: a nationwide cohort study in Denmark. *Hepatology* 1998;28:921–925.
- [50] Yamamoto S, Kubo S, Hai S, Uenishi T, Yamamoto T, Shuto T, et al. Hepatitis C virus infection as a likely etiology of intrahepatic cholangiocarcinoma. *Cancer Sci* 2004;95:592–595.
- [51] El-Serag HB, Engels EA, Landgren O, Chiao E, Henderson L, Amaratunge HC, et al. Risk of hepatobiliary and pancreatic cancers after hepatitis C virus infection: a population-based study of U.S. veterans. *Hepatology* 2009;49:116–123.
- [52] Lee S, Oh SY, Kim BG, Kwon HC, Kim SH, Rho MH, et al. Second-line treatment with a combination of continuous 5-fluorouracil, doxorubicin, and mitomycin-C (conti-FAM) in gemcitabine-pretreated pancreatic and biliary tract cancer. *Am J Clin Oncol* 2009;32:348–352.
- [53] Shaib YH, El-Serag HB, Nooka AK, Thomas M, Brown TD, Patt YZ, et al. Risk factors for intrahepatic and extrahepatic cholangiocarcinoma: a hospital-based case-control study. *Am J Gastroenterol* 2007;102:1016–1021.
- [54] Lee CH, Chang CJ, Lin YJ, Yeh CN, Chen MF, Hsieh SY. Viral hepatitis-associated intrahepatic cholangiocarcinoma shares common disease processes with hepatocellular carcinoma. *Br J Cancer* 2009;100:1765–1770.
- [55] Peng NF, Li LQ, Qin X, Guo Y, Peng T, Xiao KY, et al. Evaluation of risk factors and clinicopathologic features for intrahepatic cholangiocarcinoma in Southern China: a possible role of hepatitis B virus. *Ann Surg Oncol* 2011;18:1258–1266.
- [56] Grainge MJ, West J, Solaymani-Dodaran M, Aithal GP, Card TR. The antecedents of biliary cancer: a primary care case-control study in the United Kingdom. *Br J Cancer* 2009;100:178–180.
- [57] Welzel TM, Graubard BI, Zeuzem S, El-Serag HB, Davila JA, McGlynn KA. Metabolic syndrome increases the risk of primary liver cancer in the United States: a study in the SEER-Medicare database. *Hepatology* 2011;54:463–471.
- [58] Sia D, Hoshida Y, Villanueva A, Roayaie S, Ferrer J, Tabak B, et al. Integrative molecular analysis of intrahepatic cholangiocarcinoma reveals 2 classes that have different outcomes. *Gastroenterology* 2013;144:829–840.
- [59] Sia D, Tovar V, Moeini A, Llovet JM. Intrahepatic cholangiocarcinoma: pathogenesis and rationale for molecular therapies. *Oncogene* 2013;32:4861–4870.
- [60] Andersen JB, Spee B, Blechacz BR, Avital I, Komuta M, Barbour A, et al. Genomic and genetic characterization of cholangiocarcinoma identifies therapeutic targets for tyrosine kinase inhibitors. *Gastroenterology* 2012;142:e1015.
- [61] Andersen JB, Thorgeirsson SS. Genetic profiling of intrahepatic cholangiocarcinoma. *Curr Opin Gastroenterol* 2012;28:266–272.
- [62] Woo HG, Lee JH, Yoon JH, Kim CY, Lee HS, Jang JJ, et al. Identification of a cholangiocarcinoma-like gene expression trait in hepatocellular carcinoma. *Cancer Res* 2010;70:3034–3041.
- [63] Oishi N, Kumar MR, Roessler S, Ji J, Forgues M, Budhu A, et al. Transcriptomic profiling reveals hepatic stem-like gene signatures and interplay of miR-200c and epithelial-mesenchymal transition in intrahepatic cholangiocarcinoma. *Hepatology* 2012;56:1792–1803.
- [64] Chiang DY, Villanueva A, Hoshida Y, Peix J, Newell P, Minguez B, et al. Focal gains of VEGFA and molecular classification of hepatocellular carcinoma. *Cancer Res* 2008;68:6779–6788.
- [65] Tannapfel A, Benicke M, Katalinic A, Uhlmann D, Kockerling F, Hauss J, et al. Frequency of p16(INK4A) alterations and K-ras mutations in intrahepatic cholangiocarcinoma of the liver. *Gut* 2000;47:721–727.
- [66] Voss JS, Holtegaard LM, Kerr SE, Fritcher EG, Roberts LR, Gores GJ, et al. Molecular profiling of cholangiocarcinoma shows potential for targeted therapy treatment decisions. *Hum Pathol* 2013;44:1216–1222.
- [67] O'Dell MR, Huang JL, Whitney-Miller CL, Deshpande V, Rothberg P, Grose V, et al. Kras(G12D) and p53 mutation cause primary intrahepatic cholangiocarcinoma. *Cancer Res* 2012;72:1557–1567.
- [68] Hezel AF, Deshpande V, Zhu AX. Genetics of biliary tract cancers and emerging targeted therapies. *J Clin Oncol* 2010;28:3531–3540.
- [69] Farazi PA, Zeisberg M, Glickman J, Zhang Y, Kalluri R, DePinho RA. Chronic bile duct injury associated with fibrotic matrix microenvironment provokes cholangiocarcinoma in p53-deficient mice. *Cancer Res* 2006;66:6622–6627.
- [70] Tannapfel A, Sommerer F, Benicke M, Katalinic A, Uhlmann D, Witzigmann H, et al. Mutations of the BRAF gene in cholangiocarcinoma but not in hepatocellular carcinoma. *Cut* 2003;52:706–712.
- [71] Borger DR, Tanabe KK, Fan KC, Lopez HU, Fantin VR, Straley KS, et al. Frequent mutation of isocitrate dehydrogenase (IDH)1 and IDH2 in cholangiocarcinoma identified through broad-based tumor genotyping. *Oncologist* 2012;17:72–79.
- [72] Wang P, Dong Q, Zhang C, Kuan PF, Liu Y, Jeck WR, et al. Mutations in isocitrate dehydrogenase 1 and 2 occur frequently in intrahepatic cholangiocarcinomas and share hypermethylation targets with glioblastomas. *Oncogene* 2013;32:3091–3100.
- [73] Ong CK, Subimerb C, Pairojkul C, Wongkham S, Cutcutache I, Yu W, et al. Exome sequencing of liver fluke-associated cholangiocarcinoma. *Nat Genet* 2012;44:690–693.
- [74] Koo SH, Ihm CH, Kwon KC, Park JW, Kim JM, Kong G. Genetic alterations in hepatocellular carcinoma and intrahepatic cholangiocarcinoma. *Cancer Genet Cytogenet* 2001;130:22–28.
- [75] Wong N, Li L, Tsang K, Lai PB, To KF, Johnson PJ. Frequent loss of chromosome 3p and hypermethylation of RASSF1A in cholangiocarcinoma. *J Hepatol* 2002;37:633–639.
- [76] Uhm KO, Park YN, Lee JY, Yoon DS, Park SH. Chromosomal imbalances in Korean intrahepatic cholangiocarcinoma by comparative genomic hybridization. *Cancer Genet Cytogenet* 2005;157:37–41.
- [77] Homayounfar K, Gunawan B, Cameron S, Haller F, Baumhoer D, Uecker S, et al. Pattern of chromosomal aberrations in primary liver cancers identified by comparative genomic hybridization. *Hum Pathol* 2009;40:834–842.
- [78] Lee JY, Park YN, Uhm KO, Park SY, Park SH. Genetic alterations in intrahepatic cholangiocarcinoma as revealed by degenerate oligonucleotide primed PCR-comparative genomic hybridization. *J Korean Med Sci* 2004;19:682–687.
- [79] Wu YM, Su F, Kalyana-Sundaram S, Khazanov N, Ateeq B, Cao X, et al. Identification of targetable FGFR gene fusions in diverse cancers. *Cancer Discov* 2013;3:636–647.
- [80] Arai Y, Totoki Y, Hosoda F, Shirota T, Hama N, Nakamura H, et al. FGFR2 tyrosine kinase fusions define a unique molecular subtype of cholangiocarcinoma. *Hepatology* 2013. <http://dx.doi.org/10.1002/hep.26890>.
- [81] Chen L, Yan HX, Yang W, Hu L, Yu LX, Liu Q, et al. The role of microRNA expression pattern in human intrahepatic cholangiocarcinoma. *J Hepatol* 2009;50:358–369.
- [82] Tannapfel A, Sommerer F, Benicke M, Weinans L, Katalinic A, Geissler F, et al. Genetic and epigenetic alterations of the INK4a-ARF pathway in cholangiocarcinoma. *J Pathol* 2002;197:624–631.
- [83] Isomoto H, Mott JL, Kobayashi S, Werneburg NW, Bronk SF, Haan S, et al. Sustained IL-6/STAT-3 signaling in cholangiocarcinoma cells due to SOCS-3 epigenetic silencing. *Gastroenterology* 2007;132:384–396.
- [84] Tischoff I, Markwarth A, Witzigmann H, Uhlmann D, Hauss J, Mir-mohammadsadegh A, et al. Allele loss and epigenetic inactivation of 3p21.3 in malignant liver tumors. *Int J Cancer* 2005;115:684–689.
- [85] Chan-On W, Nairismagi ML, Ong CK, Lim WK, Dima S, Pairojkul C, et al. Exome sequencing identifies distinct mutational patterns in liver fluke-related and non-infection-related bile duct cancers. *Nat Genet* 2013;45:1474–1478.
- [86] Jiao Y, Pawlik TM, Anders RA, Selaru FM, Stoppel MM, Lucas DJ, et al. Exome sequencing identifies frequent inactivating mutations in BAP1, ARID1A and PBRM1 in intrahepatic cholangiocarcinomas. *Nat Genet* 2013;45:1470–1473.
- [87] Park J, Tadlock L, Gores GJ, Patel T. Inhibition of interleukin 6-mediated mitogen-activated protein kinase activation attenuates growth of a cholangiocarcinoma cell line. *Hepatology* 1999;30:1128–1133.
- [88] Isomoto H, Kobayashi S, Werneburg NW, Bronk SF, Guicciardi ME, Frank DA, et al. Interleukin 6 upregulates myeloid cell leukemia-1 expression through a STAT3 pathway in cholangiocarcinoma cells. *Hepatology* 2005;42:1329–1338.
- [89] Kobayashi S, Werneburg NW, Bronk SF, Kaufmann SH, Gores GJ. Interleukin-6 contributes to Mcl-1 up-regulation and TRAIL resistance via an Akt-signaling pathway in cholangiocarcinoma cells. *Gastroenterology* 2005;128:2054–2065.
- [90] Yoshikawa D, Ojima H, Iwasaki M, Hiraoka N, Kosuge T, Kasai S, et al. Clinicopathological and prognostic significance of EGFR, VEGF, and HER2 expression in cholangiocarcinoma. *Br J Cancer* 2008;98:418–425.
- [91] Endo K, Yoon BI, Pairojkul C, Demetris AJ, Sirica AE. ERBB-2 overexpression and cyclooxygenase-2 up-regulation in human cholangiocarcinoma and risk conditions. *Hepatology* 2002;36:439–450.
- [92] Nakazawa K, Dobashi Y, Suzuki S, Fujii H, Takeda Y, Ooi A. Amplification and overexpression of c-erbB-2, epidermal growth factor receptor, and c-met in biliary tract cancers. *J Pathol* 2005;206:356–365.
- [93] Terada T, Nakanuma Y, Sirica AE. Immunohistochemical demonstration of MET overexpression in human intrahepatic cholangiocarcinoma and in hepatolithiasis. *Hum Pathol* 1998;29:175–180.

Guidelines

- [94] Miyamoto M, Ojima H, Iwasaki M, Shimizu H, Kokubu A, Hiraoka N, et al. Prognostic significance of overexpression of c-Met oncoprotein in cholangiocarcinoma. *Br J Cancer* 2011;105:131–138.
- [95] Radaeva S, Ferreira-Gonzalez A, Sirica AE. Overexpression of C-NEU and C-MET during rat liver cholangiocarcinogenesis: a link between biliary intestinal metaplasia and mucin-producing cholangiocarcinoma. *Hepatology* 1999;29:1453–1462.
- [96] Slamon DJ, Leyland-Jones B, Shak S, Fuchs H, Paton V, Bajamonde A, et al. Use of chemotherapy plus a monoclonal antibody against HER2 for metastatic breast cancer that overexpresses HER2. *N Engl J Med* 2001;344:783–792.
- [97] Tsao MS, Sakurada A, Cutz JC, Zhu CQ, Kamel-Reid S, Squire J, et al. Erlotinib in lung cancer – molecular and clinical predictors of outcome. *N Engl J Med* 2005;353:133–144.
- [98] Kwak EL, Bang YJ, Camidge DR, Shaw AT, Solomon B, Maki RG, et al. Anaplastic lymphoma kinase inhibition in non-small-cell lung cancer. *N Engl J Med* 2010;363:1693–1703.
- [99] Flaherty KT, Puzanov I, Kim KB, Ribas A, McArthur GA, Sosman JA, et al. Inhibition of mutated, activated BRAF in metastatic melanoma. *N Engl J Med* 2010;363:809–819.
- [100] Obama K, Ura K, Li M, Katagiri T, Tsunoda T, Nomura A, et al. Genome-wide analysis of gene expression in human intrahepatic cholangiocarcinoma. *Hepatology* 2005;41:1339–1348.
- [101] Jinawath N, Chamgramol Y, Furukawa Y, Obama K, Tsunoda T, Sripa B, et al. Comparison of gene expression profiles between *Opisthorchis viverrini* and non-*Opisthorchis viverrini* associated human intrahepatic cholangiocarcinoma. *Hepatology* 2006;44:1025–1038.
- [102] Hamilton S. Pathology and genetics of tumours of the digestive system. Lyon: IARC Press; 2000.
- [103] Nakanuma Y, Sato Y, Harada K, Sasaki M, Xu J, Ikeda H. Pathological classification of intrahepatic cholangiocarcinoma based on a new concept. *World J Hepatol* 2010;2:419–427.
- [104] Nakajima T, Kondo Y, Miyazaki M, Okui K. A histopathologic study of 102 cases of intrahepatic cholangiocarcinoma: histologic classification and modes of spreading. *Hum Pathol* 1988;19:1228–1234.
- [105] Nakanuma Y, Harada K, Ishikawa A, Zen Y, Sasaki M. Anatomic and molecular pathology of intrahepatic cholangiocarcinoma. *J Hepatobiliary Pancreat Surg* 2003;10:265–281.
- [106] Nakanuma Y, Sasaki M, Ikeda H, Sato Y, Zen Y, Kosaka K, et al. Pathology of peripheral intrahepatic cholangiocarcinoma with reference to tumorigenesis. *Hepatol Res* 2008;38:325–334.
- [107] Nakanuma Y, Xu J, Harada K, Sato Y, Sasaki M, Ikeda H, et al. Pathological spectrum of intrahepatic cholangiocarcinoma arising in non-biliary chronic advanced liver diseases. *Pathol Int* 2011;61:298–305.
- [108] Vilana R, Forner A, Bianchi L, Garcia-Criado A, Rimola J, de Lope CR, et al. Intrahepatic peripheral cholangiocarcinoma in cirrhosis patients may display a vascular pattern similar to hepatocellular carcinoma on contrast-enhanced ultrasound. *Hepatology* 2010;51:2020–2029.
- [109] Rimola J, Forner A, Reig M, Vilana R, de Lope CR, Ayuso C, et al. Cholangiocarcinoma in cirrhosis: absence of contrast washout in delayed phases by magnetic resonance imaging avoids misdiagnosis of hepatocellular carcinoma. *Hepatology* 2009;50:791–798.
- [110] Goodman ZD. Neoplasms of the liver. *Mod Pathol* 2007;20:S49–S60.
- [111] Cabibi D, Licata A, Barresi E, Craxi A, Aragona F. Expression of cytokeratin 7 and 20 in pathological conditions of the bile tract. *Pathol Res Pract* 2003;199:65–70.
- [112] Rullier A, Le Bail B, Fawaz R, Blanc JF, Saric J, Bioulac-Sage P. Cytokeratin 7 and 20 expression in cholangiocarcinomas varies along the biliary tract but still differs from that in colorectal carcinoma metastasis. *Am J Surg Pathol* 2000;24:870–876.
- [113] Valls C, Guma A, Puig I, Sanchez A, Andia E, Serrano T, et al. Intrahepatic peripheral cholangiocarcinoma: CT evaluation. *Abdom Imaging* 2000;25:490–496.
- [114] Kim JH, Won HJ, Shin YM, Kim KA, Kim PN. Radiofrequency ablation for the treatment of primary intrahepatic cholangiocarcinoma. *AJR Am J Roentgenol* 2011;196:W205–W209.
- [115] Kim JH, Won HJ, Shin YM, Kim PN, Lee SG, Hwang S. Radiofrequency ablation for recurrent intrahepatic cholangiocarcinoma after curative resection. *Eur J Radiol* 2011;80:e221–e225.
- [116] Hamrick-Turner J, Abbott PL, Ros PR. Intrahepatic cholangiocarcinoma: MR appearance. *AJR Am J Roentgenol* 1992;158:77–79.
- [117] Fan ZM, Yamashita Y, Harada M, Baba Y, Yamamoto H, Matsukawa T, et al. Intrahepatic cholangiocarcinoma: spin-echo and contrast-enhanced dynamic MR imaging. *AJR Am J Roentgenol* 1993;161:313–317.
- [118] Murakami T, Nakamura H, Tsuda K, Ishida T, Tomoda K, Hori S, et al. Contrast-enhanced MR imaging of intrahepatic cholangiocarcinoma: pathologic correlation study. *J Magn Reson Imaging* 1995;5:165–170.
- [119] Anderson CD, Rice MH, Pinson CW, Chapman WC, Chari RS, Delbeke D. Fluorodeoxyglucose PET imaging in the evaluation of gallbladder carcinoma and cholangiocarcinoma. *J Gastrointest Surg* 2004;8:90–97.
- [120] Delbeke D, Martin WH, Sandler MP, Chapman WC, Wright Jr JK, Pinson CW. Evaluation of benign vs. malignant hepatic lesions with positron emission tomography. *Arch Surg* 1998;133:510–515. [discussion 515–516].
- [121] Kim YJ, Yun M, Lee WJ, Kim KS, Lee JD. Usefulness of 18F-FDG PET in intrahepatic cholangiocarcinoma. *Eur J Nucl Med Mol Imaging* 2003;30:1467–1472.
- [122] Lan BY, Kwee SA, Wong LL. Positron emission tomography in hepatobiliary and pancreatic malignancies: a review. *Am J Surg* 2012;204:232–241.
- [123] Xu HX, Chen LD, Liu LN, Zhang YF, Guo LH, Liu C. Contrast-enhanced ultrasound of intrahepatic cholangiocarcinoma: correlation with pathological examination. *Br J Radiol* 2012;85:1029–1037.
- [124] Li R, Zhang X, Ma KS, Li XW, Xia F, Zhong H, et al. Dynamic enhancing vascular pattern of intrahepatic peripheral cholangiocarcinoma on contrast-enhanced ultrasound: the influence of chronic hepatitis and cirrhosis. *Abdom Imaging* 2013;38:112–119.
- [125] Chong YS, Kim YK, Lee MW, Kim SH, Lee WJ, Rhim HC, et al. Differentiating mass-forming intrahepatic cholangiocarcinoma from atypical hepatocellular carcinoma using gadoteric acid-enhanced MRI. *Clin Radiol* 2012;67:766–773.
- [126] Patel AH, Harnois DM, Klee GG, LaRusso NF, Gores GJ. The utility of CA 19-9 in the diagnoses of cholangiocarcinoma in patients without primary sclerosing cholangitis. *Am J Gastroenterol* 2000;95:204–207.
- [127] Tamandl D, Herberger B, Gruenberger B, Puhalla H, Klinger M, Gruenberger T. Influence of hepatic resection margin on recurrence and survival in intrahepatic cholangiocarcinoma. *Ann Surg Oncol* 2008;15:2787–2794.
- [128] Uenishi T, Yamazaki O, Tanaka H, Takemura S, Yamamoto T, Tanaka S, et al. Serum cytokeratin 19 fragment (CYFRA21-1) as a prognostic factor in intrahepatic cholangiocarcinoma. *Ann Surg Oncol* 2008;15:583–589.
- [129] Karakatsani A, Papaconstantinou I, Gazouli M, Lyberopoulou A, Polymeneas G, Voros D. Expression of microRNAs, miR-21, miR-31, miR-122, miR-145, miR-146a, miR-200c, miR-221, miR-222, and miR-223 in patients with hepatocellular carcinoma or intrahepatic cholangiocarcinoma and its prognostic significance. *Mol Carcinog* 2013;52:297–303.
- [130] Nishino R, Honda M, Yamashita T, Takatori H, Minato H, Zen Y, et al. Identification of novel candidate tumour marker genes for intrahepatic cholangiocarcinoma. *J Hepatol* 2008;49:207–216.
- [131] Schmitz KJ, Lang H, Frey UH, Sotiropoulos GC, Wohlschlaeger J, Reis H, et al. GNAS1 T393C polymorphism is associated with clinical course in patients with intrahepatic cholangiocarcinoma. *Neoplasia* 2007;9:159–165.
- [132] Hann LE, Schwartz LH, Panicek DM, Bach AM, Fong Y, Blumgart LH. Tumor involvement in hepatic veins: comparison of MR imaging and US for preoperative assessment. *Radiology* 1998;206:651–656.
- [133] Bach AM, Hann LE, Brown KT, Getrajdman GI, Herman SK, Fong Y, et al. Portal vein evaluation with US: comparison to angiography combined with CT arterial portography. *Radiology* 1996;201:149–154.
- [134] Corvera CU, Blumgart LH, Akhurst T, DeMatteo RP, D'Angelica M, Fong Y, et al. 18F-fluorodeoxyglucose positron emission tomography influences management decisions in patients with biliary cancer. *J Am Coll Surg* 2008;206:57–65.
- [135] Kim JY, Kim MH, Lee TY, Hwang CY, Kim JS, Yun SC, et al. Clinical role of 18F-FDG PET-CT in suspected and potentially operable cholangiocarcinoma: a prospective study compared with conventional imaging. *Am J Gastroenterol* 2008;103:1145–1151.
- [136] Greene FL. The American Joint Committee on Cancer: updating the strategies in cancer staging. *Bull Am Coll Surg* 2002;87:13–15.
- [137] Edge SB, Compton CC. The American Joint Committee on Cancer: the 7th edition of the AJCC cancer staging manual and the future of TNM. *Ann Surg Oncol* 2010;17:1471–1474.
- [138] Tsai S, Nathan H, Pawlik TM. Primary liver cancer: intrahepatic cholangiocarcinoma emerges from the shadows. *Updates Surg* 2010;62:5–9.
- [139] Nathan H, Pawlik TM. Staging of intrahepatic cholangiocarcinoma. *Curr Opin Gastroenterol* 2010;26:269–273.
- [140] Yamasaki S. Intrahepatic cholangiocarcinoma: macroscopic type and stage classification. *J Hepatobiliary Pancreat Surg* 2003;10:288–291.
- [141] Okabayashi T, Yamamoto J, Kosuge T, Shimada K, Yamasaki S, Takayama T, et al. A new staging system for mass-forming intrahepatic cholangiocarcinoma: analysis of preoperative and postoperative variables. *Cancer* 2001;92:2374–2383.

- [142] Nathan H, Aloia TA, Vauthey JN, Abdalla EK, Zhu AX, Schulick RD, et al. A proposed staging system for intrahepatic cholangiocarcinoma. *Ann Surg Oncol* 2009;16:14–22.
- [143] Farges O, Fuks D, Le Treut YP, Azoulay D, Laurent A, Bachellier P, et al. AJCC 7th edition of TNM staging accurately discriminates outcomes of patients with resectable intrahepatic cholangiocarcinoma: by the AFC-IHCC-2009 study group. *Cancer* 2011;117:2170–2177.
- [144] Chung YE, Kim MJ, Park YN, Choi JY, Pyo JY, Kim YC, et al. Varying appearances of cholangiocarcinoma: radiologic-pathologic correlation. *Radiographics* 2009;29:683–700.
- [145] Manfredi R, Barbaro B, Masselli G, Vecchioli A, Marano P. Magnetic resonance imaging of cholangiocarcinoma. *Semin Liver Dis* 2004;24:155–164.
- [146] Bruix J, Sherman M. Management of hepatocellular carcinoma. *Hepatology* 2005;42:1208–1236.
- [147] Weber SM, Jarnagin WR, Klimstra D, DeMatteo RP, Fong Y, Blumgart LH. Intrahepatic cholangiocarcinoma: resectability, recurrence pattern, and outcomes. *J Am Coll Surg* 2001;193:384–391.
- [148] Tan JC, Coburn NG, Baxter NN, Kiss A, Law CH. Surgical management of intrahepatic cholangiocarcinoma – a population-based study. *Ann Surg Oncol* 2008;15:600–608.
- [149] de Jong MC, Nathan H, Sotiropoulos GC, Paul A, Alexandrescu S, Marques H, et al. Intrahepatic cholangiocarcinoma: an international multi-institutional analysis of prognostic factors and lymph node assessment. *J Clin Oncol* 2011;29:3140–3145.
- [150] Sotiropoulos GC, Bockhorn M, Sgourakis G, Brokalaki EI, Molmenti EP, Neuhauser M, et al. R0 liver resections for primary malignant liver tumors in the noncirrhotic liver: a diagnosis-related analysis. *Dig Dis Sci* 2009;54:887–894.
- [151] Endo I, Gonen M, Yopp AC, Dalal KM, Zhou Q, Klimstra D, et al. Intrahepatic cholangiocarcinoma: rising frequency, improved survival, and determinants of outcome after resection. *Ann Surg* 2008;248:84–96.
- [152] Konstadoulakis MM, Roayaie S, Gomatos IP, Labow D, Fiel MI, Miller CM, et al. Fifteen-year, single-center experience with the surgical management of intrahepatic cholangiocarcinoma: operative results and long-term outcome. *Surgery* 2008;143:366–374.
- [153] Lang H, Sotiropoulos GC, Sgourakis G, Schmitz KJ, Paul A, Hilgard P, et al. Operations for intrahepatic cholangiocarcinoma: single-institution experience of 158 patients. *J Am Coll Surg* 2009;208:218–228.
- [154] Nakagohri T, Kinoshita T, Konishi M, Takahashi S, Gotohda N. Surgical outcome and prognostic factors in intrahepatic cholangiocarcinoma. *World J Surg* 2008;32:2675–2680.
- [155] Shimada K, Sano T, Nara S, Esaki M, Sakamoto Y, Kosuge T, et al. Therapeutic value of lymph node dissection during hepatectomy in patients with intrahepatic cholangiocellular carcinoma with negative lymph node involvement. *Surgery* 2009;145:411–416.
- [156] Nakagawa T, Kamiyama T, Kurauchi N, Matsushita M, Nakanishi K, Kamachi H, et al. Number of lymph node metastases is a significant prognostic factor in intrahepatic cholangiocarcinoma. *World J Surg* 2005;29:728–733.
- [157] Choi SB, Kim KS, Choi JY, Park SW, Choi JS, Lee WJ, et al. The prognosis and survival outcome of intrahepatic cholangiocarcinoma following surgical resection: association of lymph node metastasis and lymph node dissection with survival. *Ann Surg Oncol* 2009;16:3048–3056.
- [158] Yamamoto M, Takasaki K, Otsubo T, Katsuragawa H, Katagiri S. Recurrence after surgical resection of intrahepatic cholangiocarcinoma. *J Hepatobiliary Pancreat Surg* 2001;8:154–157.
- [159] Uenishi T, Kubo S, Yamazaki O, Yamada T, Sasaki Y, Nagano H, et al. Indications for surgical treatment of intrahepatic cholangiocarcinoma with lymph node metastases. *J Hepatobiliary Pancreat Surg* 2008;15:417–422.
- [160] Paik KY, Jung JC, Heo JS, Choi SH, Choi DW, Kim YI. What prognostic factors are important for resected intrahepatic cholangiocarcinoma? *J Gastroenterol Hepatol* 2008;23:766–770.
- [161] Ohtsuka M, Ito H, Kimura F, Shimizu H, Togawa A, Yoshidome H, et al. Results of surgical treatment for intrahepatic cholangiocarcinoma and clinicopathological factors influencing survival. *Br J Surg* 2002;89:1525–1531.
- [162] Nuzzo G, Giuliani F, Ardito F, Giovannini I, Aldrighetti L, Belli G, et al. Improvement in perioperative and long-term outcome after surgical treatment of hilar cholangiocarcinoma: results of an Italian multicenter analysis of 440 patients. *Arch Surg* 2012;147:26–34.
- [163] Jaeck D. The significance of hepatic pedicle lymph nodes metastases in surgical management of colorectal liver metastases and of other liver malignancies. *Ann Surg Oncol* 2003;10:1007–1011.
- [164] Hyder O, Hatzaras I, Sotiropoulos GC, Paul A, Alexandrescu S, Marques H, et al. Recurrence after operative management of intrahepatic cholangiocarcinoma. *Surgery* 2013;153:811–818.
- [165] Takada T, Nimura Y, Katoh H, Nagakawa T, Nakayama T, Matsushiro T, et al. Prospective randomized trial of 5-fluorouracil, doxorubicin, and mitomycin C for non-resectable pancreatic and biliary carcinoma: multicenter randomized trial. *Hepatogastroenterology* 1998;45:2020–2026.
- [166] Neoptolemos JP, Stocken DD, Friess H, Bassi C, Dunn JA, Hickey H, et al. A randomized trial of chemoradiotherapy and chemotherapy after resection of pancreatic cancer. *N Engl J Med* 2004;350:1200–1210.
- [167] Neoptolemos JP, Moore MJ, Cox TF, Valle JW, Palmer DH, McDonald AC, et al. Effect of adjuvant chemotherapy with fluorouracil plus folinic acid or gemcitabine vs. observation on survival in patients with resected periampullary adenocarcinoma: the ESPAC-3 periampullary cancer randomized trial. *JAMA* 2012;308:147–156.
- [168] Darwish Murad S, Kim WR, Harnois DM, Douglas DD, Burton J, Kulik LM, et al. Efficacy of neoadjuvant chemoradiation, followed by liver transplantation, for perihilar cholangiocarcinoma at 12 US centers. *Gastroenterology* 2012;143:88–98, [e83; quiz e14].
- [169] Shimoda M, Farmer DG, Colquhoun SD, Rosove M, Ghobrial RM, Yersiz H, et al. Liver transplantation for cholangiocellular carcinoma: analysis of a single-center experience and review of the literature. *Liver Transpl* 2001;7:1023–1033.
- [170] Fu BS, Zhang T, Li H, Yi SH, Wang GS, Xu C, et al. The role of liver transplantation for intrahepatic cholangiocarcinoma: a single-center experience. *Eur Surg Res* 2011;47:218–221.
- [171] Robles R, Figueras J, Turrion VS, Margarit C, Moya A, Varo E, et al. Spanish experience in liver transplantation for hilar and peripheral cholangiocarcinoma. *Ann Surg* 2004;239:265–271.
- [172] Sotiropoulos GC, Kaiser GM, Lang H, Molmenti EP, Beckebaum S, Fouzas I, et al. Liver transplantation as a primary indication for intrahepatic cholangiocarcinoma: a single-center experience. *Transplant Proc* 2008;40:3194–3195.
- [173] Hong JC, Jones CM, Duffy JP, Petrowsky H, Farmer DG, French S, et al. Comparative analysis of resection and liver transplantation for intrahepatic and hilar cholangiocarcinoma: a 24-year experience in a single center. *Arch Surg* 2011;146:683–689.
- [174] Hong JC, Petrowsky H, Kaldas FM, Farmer DG, Durazo FA, Finn RS, et al. Predictive index for tumor recurrence after liver transplantation for locally advanced intrahepatic and hilar cholangiocarcinoma. *J Am Coll Surg* 2011;212:514–520, [discussion 520–511].
- [175] Rana A, Hong JC. Orthotopic liver transplantation in combination with neoadjuvant therapy: a new paradigm in the treatment of unresectable intrahepatic cholangiocarcinoma. *Curr Opin Gastroenterol* 2012;28:258–265.
- [176] Wolfe RA, Roys EC, Merion RM. Trends in organ donation and transplantation in the United States, 1999–2008. *Am J Transplant* 2010;10:961–972.
- [177] Maganty K, Levi D, Moon J, Bejarano PA, Arosemena L, Tzakis A, et al. Combined hepatocellular carcinoma and intrahepatic cholangiocarcinoma: outcome after liver transplantation. *Dig Dis Sci* 2010;55:3597–3601.
- [178] Sapisochin G, Fidelman N, Roberts JP, Yao FY. Mixed hepatocellular cholangiocarcinoma and intrahepatic cholangiocarcinoma in patients undergoing transplantation for hepatocellular carcinoma. *Liver Transpl* 2011;17:934–942.
- [179] Morise Z, Sugioka A, Tokoro T, Tanahashi Y, Okabe Y, Kagawa T, et al. Surgery and chemotherapy for intrahepatic cholangiocarcinoma. *World J Hepatol* 2010;2:58–64.
- [180] Lazaridis KN, Gores GJ. Cholangiocarcinoma. In: Boyer T, Manns MP, Sanyal A, editors. *Elsevier*; 2011. p. 1032–1044.
- [181] Chen YX, Zeng ZC, Tang ZY, Fan J, Zhou J, Jiang W, et al. Determining the role of external beam radiotherapy in unresectable intrahepatic cholangiocarcinoma: a retrospective analysis of 84 patients. *BMC Cancer* 2010;10:492.
- [182] Zeng ZC, Tang ZY, Fan J, Zhou J, Qin LX, Ye SL, et al. Consideration of the role of radiotherapy for unresectable intrahepatic cholangiocarcinoma: a retrospective analysis of 75 patients. *Cancer J* 2006;12:113–122.
- [183] Barney BM, Olivier KR, Miller RC, Haddock MG. Clinical outcomes and toxicity using stereotactic body radiotherapy (SBRT) for advanced cholangiocarcinoma. *Radiat Oncol* 2012;7:67.
- [184] Ibarra RA, Rojas D, Snyder L, Yao M, Fabien J, Milano M, et al. Multicenter results of stereotactic body radiotherapy (SBRT) for non-resectable primary liver tumors. *Acta Oncol* 2012;51:575–583.
- [185] Shinohara ET, Mitra N, Guo M, Metz JM. Radiation therapy is associated with improved survival in the adjuvant and definitive treatment of

Guidelines

- intrahepatic cholangiocarcinoma. *Int J Radiat Oncol Biol Phys* 2008;72: 1495–1501.
- [186] Jiang W, Zeng ZC, Tang ZY, Fan J, Zhou J, Zeng MS, et al. Benefit of radiotherapy for 90 patients with resected intrahepatic cholangiocarcinoma and concurrent lymph node metastases. *J Cancer Res Clin Oncol* 2010;136:1323–1331.
- [187] Kim YI, Park JW, Kim BH, Woo SM, Kim TH, Koh YH, et al. The effect of chemoradiotherapy for unresectable advanced intrahepatic cholangiocarcinoma. *International Liver Cancer Association Meeting*; 2012.
- [188] O'Connor J, Goldstein R. Stereotactic body radiation therapy in the treatment of unresectable intrahepatic cholangiocarcinoma. *J Clin Oncol* 2011;29:abstr 335.
- [189] EASL-EORTC clinical practice guidelines. Management of hepatocellular carcinoma. *J Hepatol* 2012;56:908–943.
- [190] Hong K, Geschwind JF. Locoregional intra-arterial therapies for unresectable intrahepatic cholangiocarcinoma. *Semin Oncol* 2010;37:110–117.
- [191] Park SY, Kim JH, Yoon HJ, Lee IS, Yoon HK, Kim KP. Transarterial chemoembolization vs. supportive therapy in the palliative treatment of unresectable intrahepatic cholangiocarcinoma. *Clin Radiol* 2011;66: 322–328.
- [192] Edwards A, Ray JC. Transarterial therapies for unresectable cholangiocarcinoma: a meta-analysis. *J Vasc Interv Radiol* 2012;23:S101.
- [193] Kiefer MV, Albert M, McNally M, Robertson M, Sun W, Fraker D, et al. Chemoembolization of intrahepatic cholangiocarcinoma with cisplatin, doxorubicin, mitomycin C, ethiodol, and polyvinyl alcohol: a 2-center study. *Cancer* 2011;117:1498–1505.
- [194] Stuebs P, Habermann P, Garlipp B, Schuette K, Zierau K, Lippert H, et al. Developments of treatment of advanced intrahepatic cholangiocarcinoma: an analysis of systemic and local therapy modes in 57 patients. *J Clin Oncol* 2012;30:abstr 356.
- [195] Shen WF, Zhong W, Liu Q, Sui CJ, Huang YQ, Yang JM. Adjuvant transcatheter arterial chemoembolization for intrahepatic cholangiocarcinoma after curative surgery: retrospective control study. *World J Surg* 2011;35:2083–2091.
- [196] Aliberti C, Benea G, Tilli M, Fiorentini G. Chemoembolization (TACE) of unresectable intrahepatic cholangiocarcinoma with slow-release doxorubicin-eluting beads: preliminary results. *Cardiovasc Intervent Radiol* 2008;31:883–888.
- [197] Poggi G, Amatu A, Montagna B, Quaretti P, Minoia C, Sottani C, et al. OEM-TACE: a new therapeutic approach in unresectable intrahepatic cholangiocarcinoma. *Cardiovasc Intervent Radiol* 2009;32:1187–1192.
- [198] Kuhlmann JB, Euringer W, Spangenberg HC, Breidert M, Blum HE, Harder J, et al. Treatment of unresectable cholangiocarcinoma: conventional transarterial chemoembolization compared with drug eluting bead-transarterial chemoembolization and systemic chemotherapy. *Eur J Gastroenterol Hepatol* 2012;24:437–443.
- [199] Tanaka N, Yamakado K, Nakatsuka A, Fujii A, Matsumura K, Takeda K. Arterial chemoinfusion therapy through an implanted port system for patients with unresectable intrahepatic cholangiocarcinoma—initial experience. *Eur J Radiol* 2002;41:42–48.
- [200] Vogl TJ, Schwarz W, Eichler K, Hochmuth K, Hammerstingl R, Jacob U, et al. Hepatic intraarterial chemotherapy with gemcitabine in patients with unresectable cholangiocarcinomas and liver metastases of pancreatic cancer: a clinical study on maximum tolerable dose and treatment efficacy. *J Cancer Res Clin Oncol* 2006;132:745–755.
- [201] Shitara K, Ikami I, Munakata M, Muto O, Sakata Y. Hepatic arterial infusion of mitomycin C with degradable starch microspheres for unresectable intrahepatic cholangiocarcinoma. *Clin Oncol (R Coll Radiol)* 2008;20: 241–246.
- [202] Ibrahim SM, Mulcahy MF, Lewandowski RJ, Sato KT, Ryu RK, Masterson EJ, et al. Treatment of unresectable cholangiocarcinoma using yttrium-90 microspheres: results from a pilot study. *Cancer* 2008;113: 2119–2128.
- [203] Saxena A, Bester L, Chua TC, Chu FC, Morris DL. Yttrium-90 radiotherapy for unresectable intrahepatic cholangiocarcinoma: a preliminary assessment of this novel treatment option. *Ann Surg Oncol* 2010;17:484–491.
- [204] Hoffmann RT, Paprottka PM, Schon A, Bamberg F, Haug A, Durr EM, et al. Transarterial hepatic yttrium-90 radioembolization in patients with unresectable intrahepatic cholangiocarcinoma: factors associated with prolonged survival. *Cardiovasc Intervent Radiol* 2012;35:105–116.
- [205] Chiou YY, Hwang JJ, Chou YH, Wang HK, Chiang JH, Chang CY. Percutaneous ultrasound-guided radiofrequency ablation of intrahepatic cholangiocarcinoma. *Kaohsiung J Med Sci* 2005;21:304–309.
- [206] Carrafiello G, Lagana D, Cotta E, Mangini M, Fontana F, Bandiera F, et al. Radiofrequency ablation of intrahepatic cholangiocarcinoma: preliminary experience. *Cardiovasc Intervent Radiol* 2010;33:835–839.
- [207] Kim SA, Lee JM, Lee KB, Kim SH, Yoon SH, Han JK, et al. Intrahepatic mass-forming cholangiocarcinomas: enhancement patterns at multiphasic CT, with special emphasis on arterial enhancement pattern—correlation with clinicopathologic findings. *Radiology* 2011;260:148–157.
- [208] Haidu M, Dobrozemsky G, Schullian P, Widmann G, Klaus A, Weiss H, et al. Stereotactic radiofrequency ablation of unresectable intrahepatic cholangiocarcinomas: a retrospective study. *Cardiovasc Intervent Radiol* 2012;35:1074–1082.
- [209] Giorgio A, Calisti G, De Stefano G, Farella N, Di Sarno A, Amendola F, et al. Radiofrequency ablation for intrahepatic cholangiocarcinoma: retrospective analysis of a single centre experience. *Anticancer Res* 2011;31: 4575–4580.
- [210] Fu Y, Yang W, Wu W, Yan K, Xing BC, Chen MH. Radiofrequency ablation in the management of unresectable intrahepatic cholangiocarcinoma. *J Vasc Interv Radiol* 2012;23:642–649.
- [211] Kamphues C, Seehofer D, Eisele RM, Denecke T, Pratschke J, Neumann UP, et al. Recurrent intrahepatic cholangiocarcinoma: single-center experience using repeated hepatectomy and radiofrequency ablation. *J Hepatobiliary Pancreat Sci* 2010;17:509–515.
- [212] Livraghi T, Meloni F, Solbiati L, Zanusi G. Complications of microwave ablation for liver tumors: results of a multicenter study. *Cardiovasc Intervent Radiol* 2012;35:868–874.
- [213] Glimelius B, Hoffman K, Sjoden PO, Jacobsson G, Sellstrom H, Enander LK, et al. Chemotherapy improves survival and quality of life in advanced pancreatic and biliary cancer. *Ann Oncol* 1996;7:593–600.
- [214] Sharma A, Dwary AD, Mohanti BK, Deo SV, Pal S, Sreenivas V, et al. Best supportive care compared with chemotherapy for unresectable gall bladder cancer: a randomized controlled study. *J Clin Oncol* 2010;28: 4581–4586.
- [215] Eckel F, Schmid RM. Chemotherapy in advanced biliary tract carcinoma: a pooled analysis of clinical trials. *Br J Cancer* 2007;96:896–902.
- [216] Valle JW, Wasan H, Johnson P, Jones E, Dixon L, Swindell R, et al. Gemcitabine alone or in combination with cisplatin in patients with advanced or metastatic cholangiocarcinomas or other biliary tract tumours: a multicentre randomised phase II study – The UK ABC-01 Study. *Br J Cancer* 2009;101:621–627.
- [217] Valle J, Wasan H, Palmer DH, Cunningham D, Anthony A, Maraveyas A, et al. Cisplatin plus gemcitabine vs. gemcitabine for biliary tract cancer. *N Engl J Med* 2010;362:1273–1281.
- [218] Okusaka T, Nakachi K, Fukutomi A, Mizuno N, Ohkawa S, Funakoshi A, et al. Gemcitabine alone or in combination with cisplatin in patients with biliary tract cancer: a comparative multicentre study in Japan. *Br J Cancer* 2010;103:469–474.
- [219] Oh SY, Jeong CY, Hong SC, Kim TH, Ha CY, Kim HJ, et al. Phase II study of second line gemcitabine single chemotherapy for biliary tract cancer patients with 5-fluorouracil refractoriness. *Invest New Drugs* 2011;29: 1066–1072.
- [220] Bekaii-Saab T, Phelps MA, Li X, Saji M, Goff L, Kauh JS, et al. Multi-institutional phase II study of selumetinib in patients with metastatic biliary cancers. *J Clin Oncol* 2011;29:2357–2363.
- [221] Malka D, Trarbach T, Fartoux L, Mendiboure J, de la Fouchardiere C, Viret F, et al. A multicenter, randomized phase II trial of gemcitabine and oxaliplatin (GEMOX) alone or in combination with biweekly cetuximab in the first-line treatment of advanced biliary cancer: interim analysis of the BINGO trial. *J Clin Oncol* 2009;27:4520.
- [222] Moehler M. A randomized, double-blind, multicenter phase II AIO trial with gemcitabine plus sorafenib vs. gemcitabine plus placebo in patients with chemotherapy-naïve advanced or metastatic biliary tract cancer: first safety and efficacy data. *J Clin Oncol* 2011;29:abstr 4077.
- [223] Ko KH, Kim NK, Yim DJ, Hong SP, Park PW, Rim KS, et al. Polymorphisms of 5,10-methylenetetrahydrofolate reductase (MTHFR C677T) and thymidylate synthase enhancer region (TSER) as a risk factor of cholangiocarcinoma in a Korean population. *Anticancer Res* 2006;26:4229–4233.
- [224] Marahatta SB, Punyari P, Bhudisawasdi V, Paupairoj A, Wongkham S, Petmitr S. Polymorphism of glutathione S-transferase omega gene and risk of cancer. *Cancer Lett* 2006;236:276–281.
- [225] Hoblinger A, Grunhage F, Sauerbruch T, Lammert F. Association of the c.3972C>T variant of the multidrug resistance-associated protein 2 Gene (MRP2/ABCC2) with susceptibility to bile duct cancer. *Digestion* 2009;80: 36–39.

- [226] Wadsworth CA, Dixon PH, Wong JH, Chapman MH, McKay SC, Sharif A, et al. Genetic factors in the pathogenesis of cholangiocarcinoma. *Dig Dis* 2011;29:93–97.
- [227] Melum E, Karlsen TH, Schrumpf E, Bergquist A, Thorsby E, Boberg KM, et al. Cholangiocarcinoma in primary sclerosing cholangitis is associated with NKG2D polymorphisms. *Hepatology* 2008;47:90–96.
- [228] Huang WY, Gao YT, Rashid A, Sakoda LC, Deng J, Shen MC, et al. Selected base excision repair gene polymorphisms and susceptibility to biliary tract cancer and biliary stones: a population-based case-control study in China. *Carcinogenesis* 2008;29:100–105.
- [229] Sakoda LC, Gao YT, Chen BE, Chen J, Rosenberg PS, Rashid A, et al. Prostaglandin-endoperoxide synthase 2 (PTGS2) gene polymorphisms and risk of biliary tract cancer and gallstones: a population-based study in Shanghai, China. *Carcinogenesis* 2006;27:1251–1256.
- [230] Mihalache F, Hoblinger A, Grunhage F, Krawczyk M, Gartner BC, Acalovschi M, et al. Heterozygosity for the alpha1-antitrypsin Z allele may confer genetic risk of cholangiocarcinoma. *Aliment Pharmacol Ther* 2011;33:389–394.
- [231] Glimelius B, Jakobsen A, Graf W, Berglund A, Gadeberg C, Hansen P, et al. Bolus injection (2–4 min) vs. short-term (10–20 min) infusion of 5-fluorouracil in patients with advanced colorectal cancer: a prospective randomised trial. *Nordic Gastrointestinal Tumour Adjuvant Therapy Group. Eur J Cancer* 1998;34:674–678.
- [232] Kornek GV, Schuell B, Laengle F, Gruenberger T, Penz M, Karall K, et al. Mitomycin C in combination with capecitabine or biweekly high-dose gemcitabine in patients with advanced biliary tract cancer: a randomised phase II trial. *Ann Oncol* 2004;15:478–483.
- [233] Ducreux M, Van Cutsem E, Van Laethem JL, Gress TM, Jeziorski K, Rougier P, et al. A randomised phase II trial of weekly high-dose 5-fluorouracil with and without folinic acid and cisplatin in patients with advanced biliary tract carcinoma: results of the 40955 EORTC trial. *Eur J Cancer* 2005;41:398–403.
- [234] Rao S, Cunningham D, Hawkins RE, Hill ME, Smith D, Daniel F, et al. Phase III study of 5FU, etoposide and leucovorin (FELV) compared to epirubicin, cisplatin and 5FU (ECF) in previously untreated patients with advanced biliary cancer. *Br J Cancer* 2005;92:1650–1654.